

ACECLOFENAC INDUCED STEVENS JOHNSON SYNDROME: A RARE CASE REPORT

Hasan R., Abidi A., Saxena K.,* Ahmad A., Rizvi D. A., Thadani A.

Department of Pharmacology, *Department of Dermatology

Era's Lucknow Medical College & Hospital, Sarfarazganj, Lucknow, U.P. India.-226003

Received on : 11-02-2017

Accepted on : 13-03-2017

ABSTRACT

Aceclofenac is commonly used Non Steroidal Anti-Inflammatory Drugs (NSAIDs) for musculoskeletal pain. Though mostly it is a safe drug but there were some spurious reports of Adverse Drug Reaction (ADR) by this drug. Here we report a rare occurrence of Stevens-Johnson syndrome (SJS) / Toxic Epidermal Necrolysis (TEN) after the use of Aceclofenac. An elderly female presented to dermatology OPD with complaints of eye discharge, blackish discolouration and oedema around both the eyes and lips and a rapidly evolving rash over face and bullae and blisters all over the body. On taking history patient stated that she is taking Tab. Aceclofenac 100 mg BD since 2 days for sprain in her Right Foot. It was diagnosed as a case of drug induced SJS and Naranjo score for this adverse drug event was six, thereby making it a probable ADR. Patient was managed symptomatically and the offending drug was withdrawn. We are presenting this case to highlight the serious adverse reactions possible from a routinely prescribed and over the counter drug.

Address for correspondence

Dr. Afroz Abidi

Department of Pharmacology
Era's Lucknow Medical College &
Hospital, Lucknow-226003
Email:afrozabidi@gmail.com
Contact no: +91-8006336662

KEYWORD: Aceclofenac, Stevens-Johnson syndrome, Adverse Drug Reaction.

INTRODUCTION

Adverse drug reaction is defined as a noxious, unintended and undesirable effect which occurs due to drugs at doses used in humans for diagnosis, prophylaxis and treatment. Aceclofenac is a Non Steroidal Anti-Inflammatory Drugs (NSAID) - phenylacetic acid derivative {2-[(2, 6-dichlorophenyl) amino]-phenylacetoxyacetic acid} which is widely prescribed for musculoskeletal pain associated with rheumatic, degenerative and traumatic injury etiologies and is safe (1). It is a preferential COX-2 inhibitor and an analogue of diclofenac having additional properties to inhibit the synthesis of inflammatory cytokines such as interleukin-1, TNF, and Prostaglandin E₂ (2). Though aceclofenac is well-tolerated, with a minor incidence of gastrointestinal adverse effects (1). Other reported adverse effects are paraesthesias, dizziness, vertigo and tremor. Here, we report a case of aceclofenac induced Stevens Johnson syndrome, a clinical association that has been previously reported in very few cases in Indian population. Stevens-Johnson Syndrome (SJS) is a life-threatening, bullous cutaneous disease considered as immune-mediated reactions to drugs characterized by epidermal necrosis, extensive detachment of the epidermis, erosions of mucous membranes and severe constitutional symptoms (3).

second day and also developed severe itching and redness in both eyes since 1 day. She also complained of blackish discolouration and oedema around both the eyes and lips since 1 day (Figure1).

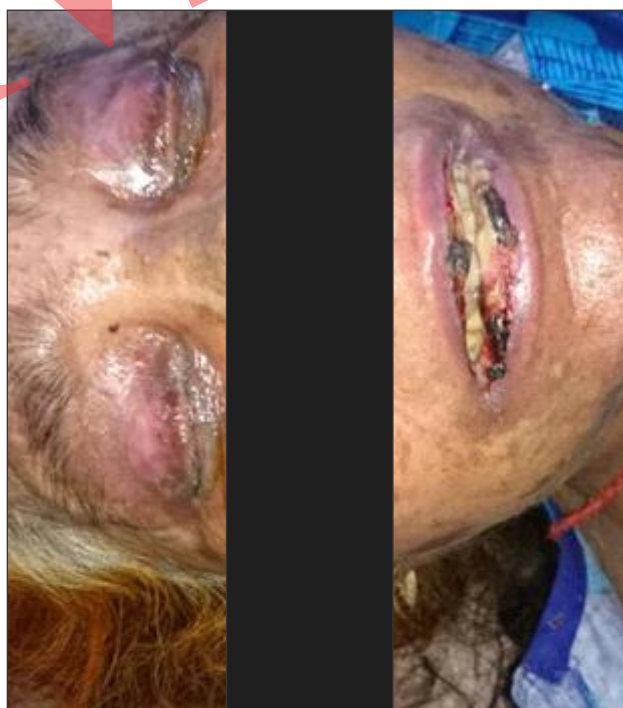

Figure1: Edema around eyes and lips

CASE REPORT

A 55 year old elderly female came to Dermatology OPD with chief complaints of purulent discharge from both the eyes since 3 days which increased on the

Simultaneously she also developed severe itching and rashes all over the body including face since 1 day. The rashes were erythematous, small in size and associated

with severe itching and mild pain. Gradually these rashes developed in bullae and blisters all over the body starting from face to hands and legs, then to abdominal region and to the back. She also developed purulent discharge from mouth and ulceration of buccal mucosa and desquamation of tongue (Figure 2).

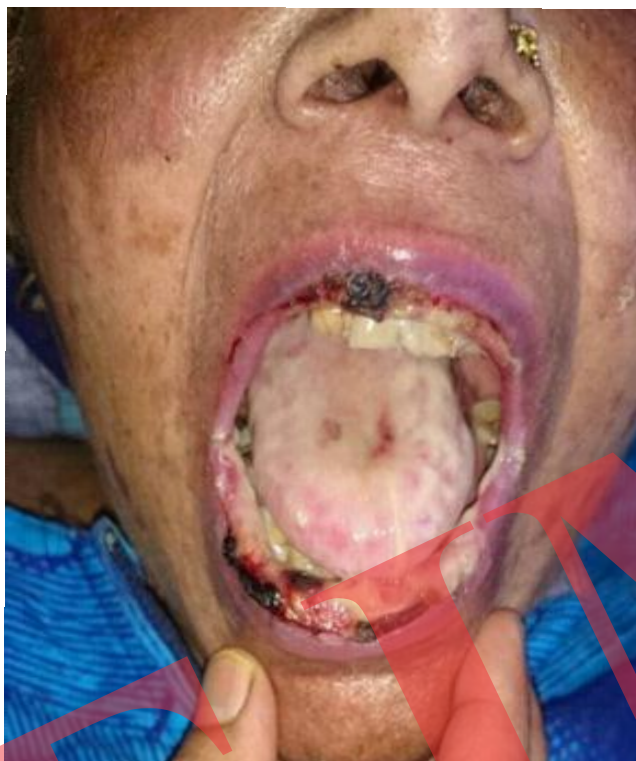

Figure 2: Desquamation of tongue with edema, crusting and bleeding of lips

She Complained of pain in joints of both hands and legs. Patient was conscious, but was unable to verbally communicate due to painful ulcers in the oral mucosa and throat. On examination patient had erythema and multiple vesicles in the oral mucosa and involving most of her face but few were disrupted vesicles with crusting and bleeding particularly severe around the lips, nose and forehead. Her temperature was 101F and Blood Pressure (BP) was 110/70 mmHg

On taking history, patient's attendant told that she was taking Tab. Aceclofenac 100mg BD since 2 days for sprain in her right foot which was prescribed by a local practitioner. The patient was not suffering from any kind of infection or any other chronic disease. Patient was diagnosed with Drug Induced Stevens Johnson Syndrome. She was immediately admitted in emergency ward and given fluid resuscitation with normal saline, intravenous corticosteroids (Hydrocortisone Hemisuccinate 100 mg I.V), antihistamines (Avil) and supportive medication

(Ranitidine 50 mg i.v, Benzocaine gel for oral ulcerations). Due to the above adverse effects, medication was withdrawn and the attendant was strictly instructed not to administer the medicine again. Her Blood Sugar (Fasting), Liver Function Tests (LFT) and Kidney Function Tests (KFT) were done and found to be normal.

Gradually the condition of the patient improved and after 2 days, crusting of rashes, bullae and blisters started developing and edema, erythema and itching subsided. (Figure 3)

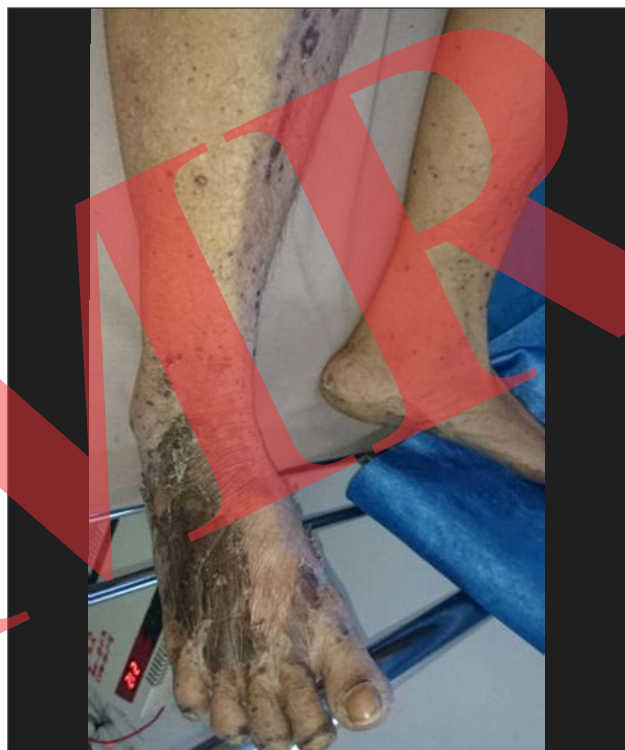

Figure 3: Crusting seen in lower limb

The Naranjo adverse drug reaction probability scale score (4) of six indicated a 'Probable' relationship between Stevens Johnson Syndrome and Aceclofenac therapy in this patient. WHO Uppsala Monitoring Centre Causality Assessment Criteria (5) also indicated a 'Probable' association with Aceclofenac.

DISCUSSION

Stevens–Johnson syndrome (SJS) also known as erythema multiforme major (6) is one of the most debilitating adverse drug reactions. There are four causative categories which includes (a) infectious (b) drug-induced (c) malignancy-related (d) idiopathic (7). It is an immune-complex–mediated hypersensitivity complex that typically involves the skin and the mucous membranes. Classification is as follows (8).

- Stevens-Johnson syndrome: A minor form of toxic epidermal necrolysis (TEN), with less

than 10% body surface area (BSA) detachment

- Overlapping Stevens-Johnson syndrome/toxic epidermal necrolysis: Detachment of 10-30% of the BSA.
- Toxic epidermal necrolysis: Detachment of more than 30% of the BSA

Drugs that are implicated to cause SJS includes penicillins and sulfa antibiotics, carbamazepine, valproic acid, lamotrigine, barbiturates, mirtazapine, infliximab, etanercept, adalimumab etc, (7) but Aceclofenac induced SJS is a rare adverse drug reaction which we have highlighted in this case report. An idiosyncratic, delayed, hypersensitivity reaction could be implicated in the pathophysiology of SJS (9). It has been recognized that drug-induced SJS is a severe hypersensitivity reaction which involves major histocompatibility class -I (MHC) restricted drug presentation and cytotoxic T lymphocytes (CTLs) expansion, which further leads to extensive keratinocyte death in skin lesions [Figure 4] (10). As the drugs are too small to trigger an immunogenic response, three mechanistic models have been

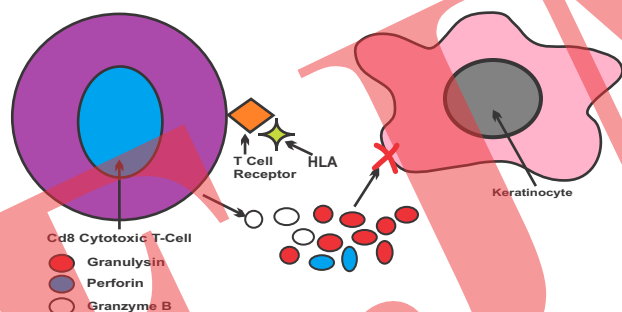


Figure 4 - The hypothesized model for apoptosis of keratinocyte in Stevens-Johnson syndrome (SJS). As illustrated, the immune response is triggered by the human leukocyte antigen (HLA) dependent presentation of an antigen (an interaction of an endogenous self-peptide with a causative drug/metabolite) to specific T cell receptors (TCRs) on the CD8 cytotoxic T cells. Upon this recognition, cytotoxic T cells produce cytokines / chemokines as well as various cytotoxic proteins to induce extensive keratinocyte apoptosis (10).

proposed to explain how small molecular synthetic compounds are recognized by T cells in an MHC-dependent fashion. These include the hapten/prohapten model, the pei model, and the altered repertoire model (10).

The hapten/prohapten concept: This concept proposes that the drug or its metabolite reacts with a self-protein through covalent binding to produce a de novo product, haptened, which then undergoes processing by the antigen resulting in generation of a novel MHC ligand that is consequently loaded onto the MHC and trafficked to the cell surface. Here it

activates the antigen-specific T lymphocytes (11,12).

The pei or pharmacological interaction with immune receptors model: This model proposes that a non-covalent, labile interaction of the drug with the MHC receptor at the cell surface is involved in MHC-dependent T cell stimulation by various drugs (13). Neither cellular metabolism nor antigen processing is required in such an interaction.

The altered repertoire model: This concept proposes that drugs or drug metabolites can bind to specific MHC molecules, within the pocket of their peptide binding grooves, with exquisite specificity, thus allowing a new repertoire of endogenous self-peptides to be bound and presented (10).

Current studies dealing with pharmacogenomics have advanced our knowledge on the genetic predispositions to adverse drug reactions. With the identification of specific HLA alleles as the predisposing factor to the disease, it therefore becomes clear that the pathogenesis of drug-mediated SJS/TEN involves MHC-restricted activation of cytotoxic T Lymphocytes (CTL) response. This response mediated through cytotoxic T lymphocytes requires several downstream signaling or release of mediators, to eventually trigger extensive keratinocyte death (14).

CONCLUSION

The main intention of this case report of drug induced SJS by Aceclofenac is to make the clinicians as well as patients aware of this ADR occurrence by Aceclofenac. It is advocated that clinicians take a proper history before prescribing Aceclofenac for pain and inflammation and early diagnosis and treatment might improve the outcome and decrease mortality in many patients of SJS. Patient education regarding the possibility of adverse drug reaction is essential to minimize the use of over the counter drug.

REFERENCES

1. Legrand E. Aceclofenac in the management of inflammatory pain. *Expert Opin Pharmacother.* 2004;5:1347-1357
2. Patel P, Patel T. Efficacy and safety of aceclofenac in osteoarthritis: A meta-analysis of randomized controlled trials. *European Journal of Rheumatology.* 2017;4(1):11-18.
3. Angadi S, Karn A. Ibuprofen induced Stevens-Johnson syndrome - toxic epidermal necrolysis in Nepal. *Asia Pacific Allergy.* 2016;6(1):70.
4. Naranjo CA, Busto U, Sellers EM, Sandor P, Ruiz I, Roberts EA *et al.* A method for estimating the probability of adverse drug reactions. *Clin Pharmacol Ther* 1981;30:239-45.

5. Zaki S. Adverse drug reaction and causality assessment scales. *Lung India*. 2011;28(2):152.
6. Brett AS, Phillips D, Lynn AW. Intravenous immunoglobulin therapy for Stevens-Johnson syndrome. *South Med J*. 2001;94(3): 342–3.
7. Tyagi S, Kumar S, Kumar A, Singla M, Singh A. Stevens-Johnson Syndrome-a life threatening skin disorder: a review *J Chem Pharm Res*. 2010;2(2):618–26
8. French LE. Toxic Epidermal Necrosis and Stevens Johnson Syndrome: Our current understanding. *Allergol Int*. 2006;55(1):9-16.
9. Madaiah A, Gowda HN. Fatal phenytoin induced Stevens–Johnson syndrome in an elderly person with metastatic lung carcinoma. *Natl J Physiol Pharm Pharmacol*. 2016;6:175–7.
10. S Shih-Chi, C Wen-Hung. Update on pathobiology in Stevens-Johnson syndrome and toxic epidermal necrolysis. *Dermatologica sinica* 2013;31:175-80.
11. Padovan E, Bauer T, Tongio MM, Kalbacher H, Weltzien HU. Penicilloyl peptides are recognized as T cell antigenic determinants in penicillin allergy. *Eur J Immunol* 1997;27:1303-7.
12. Pohl LR, Satoh H, Christ DD, Kenna JG. The immunologic and metabolic basis of drug hypersensitivities. *Annu Rev Pharmacol Toxicol* 1988;28:367-87.
13. Pichler WJ. Pharmacological interaction of drugs with antigen-specific immune receptors: the p-i concept. *Curr Opin Allergy Clin Immunol* 2002;2:301-5.
14. Viard I, Wehrli P, Bullani R, Schneider P, Holler N, Saloman D *et al.* Inhibition of toxic epidermal necrolysis by blockade of CD95 with human intravenous immunoglobulin. *Science* 1998;282: 490-3.