

PRIMARY INTRATESTICULAR RHABDOMYOSARCOMA - A RARE CASE REPORT

Nishi Tandon, Rasha Zia Usmani, Sania Zahra Rizvi, Nirupma Lal, Noorin Zaidi, S.K Bhatt*

Department Of Pathology, Department Of Surgery*

Era's Lucknow Medical College & Hospital, Sarfarazganj, Hardoi Road, Lucknow, U. P., India-226003

ABSTRACT

Rhabdomyosarcoma is one of most frequent soft tissue sarcoma of skeletal muscle origin. It occurs predominantly in Head& Neck, Genitourinary tract and extremities. The majority of cases of rhabdomyosarcoma in the genitourinary tract occurs in the bladder and paratesticular organs Primary intratesticular Rhabdomyosarcoma is very rare, have aggressive growth pattern. A 15 years old male presented with painless right testicular swelling who underwent high inguinal orchidectomy and left testis appeared normal. Complete blood count, Serum alpha- fetoprotein (1ng/ml) and Beta Human chorionic gonadotropin(<2.39) are with in normal limits. X-ray {chest} reveals multiple variable sized nodules in bilateral lungs with right hilar lymphadenopathy. ?Metastasis. HR-USG (scrotum) reveals ill-defined lobulated, heterogeneously hypoechoic, soft tissue mass with increased internal vascularity in the right scrotal region with multiple enlarged lymphnodes suggestive of neoplastic etiology. On histopathology diagnosis of rhabdomyosarcoma –Right testis was made., have aggressive growth pattern. The optimal management of paratesticular rhabdomyosarcoma remains unclear because of the rarity of the disease in adults. Radical orchidectomy with negative surgical margins followed by RPLND and chemotherapy is the recommended treatment. For the control of local recurrence and metastasis radiotherapy is recommended. The purpose of this article is to report a case of 15 years old male with primary intratesticular rhabdomyosarcoma which is very rare and our best knowledge few cases have been reported in the literature till now.

KEYWORD: Rhabdomyosarcoma, intra-testicular, orchidectomy

INTRODUCTION

Rhabdomyosarcoma was first described by Weber in 1854 (1). Rhabdomyosarcoma is one of most frequent soft tissue sarcoma of skeletal muscle origin. It occurs predominantly in Head& Neck, Genitourinary tract and extremities (2). The majority of cases of rhabdomyosarcoma in the genitourinary tract occurs in the bladder and paratesticular organs. The etiology is uncertain, however, the origin is presumed to be an overgrowth of the sarcomatous component of teratoma. Primary intratesticular Rhabdomyosarcoma is very rare and accounts for 10% of testicular tumor in children (3-5).

CASE HISTORY

A 15 years old male presented in surgical O.P.D with complains of swelling in right side of scrotum. On physical examination swelling was irreducible, firm in consistency, non tender. Complete blood count, Serum alpha-fetoprotein (1ng/ml) and Beta- chorionic gonadotropin(<2.39) are with in normal limits.

X-ray(chest)

reveals multiple variable sized nodules in bilateral lungs with right hilar lymphadenopathy. ? Metastasis.

Received on : 19-12-2017

Accepted on : 25-12-2017

Address for correspondence

Dr. Rasha Zia Usmani

Junior resident

Department of Pathology

Era's Lucknow Medical College & Hospital, Lucknow-226003

Email: rashazia15@gmail.com

Contact no: +91- 9918544316

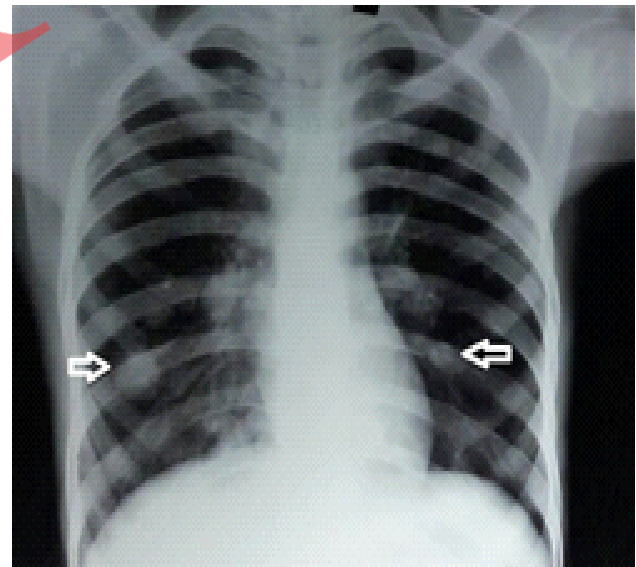


Fig1 Chest X-Ray(P.A View)

HR-USG (scrotum) reveals ill-defined lobulated, heterogeneously hypoechoic, soft tissue mass with increased internal vascularity in the right scrotal region with multiple enlarged lymphnodes suggestive of neoplastic etiology.

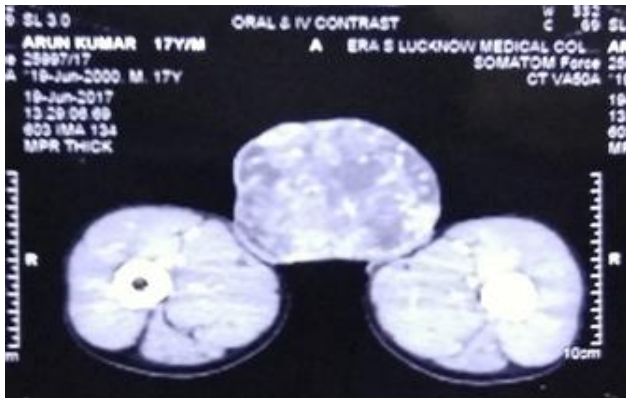

Fig2 HR-USG Scrotum

Grossly There was globular soft tissue mass with attached skin ellipse all together measuring 14.5×9×8cm. Outer surface is grey-white to grey-brown. Skin ellipse separately measures 11×11cm. Cut surface shows grey-white haemorrhagic areas and few cystic areas filled with gelatinous material.

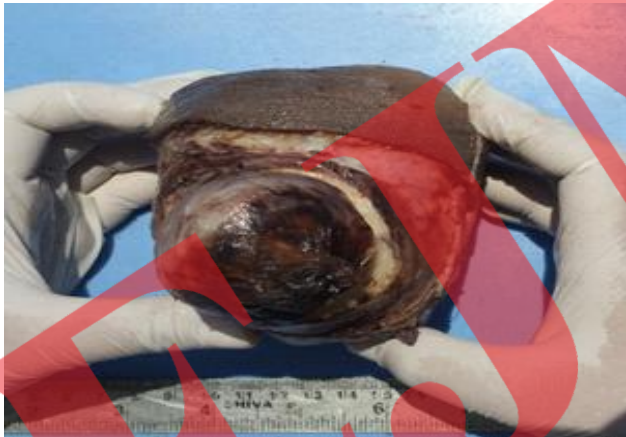


Fig3a Photograph showing gross view of right-orchidectomy specimen

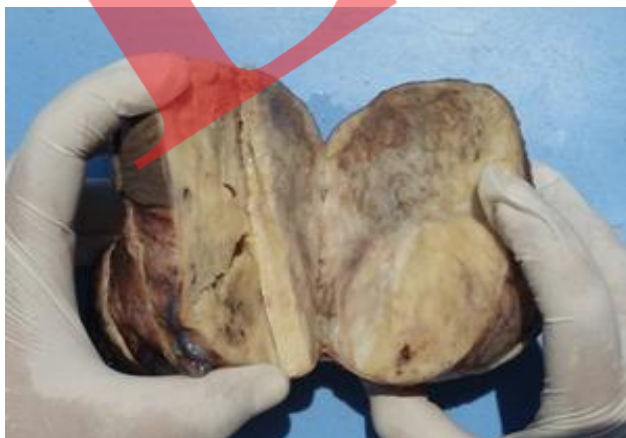

Fig3b Photograph showing cut surface having grey-white haemorrhagic areas and few cystic areas filled with gelatinous material

Microscopically

Section from the tissue shows sheets of small round to spindle shaped atypical cells. These atypical cells have pleomorphic hyperchromatic nuclei, scant eosinophilic cytoplasm with few showing prominent nucleoli. Focal area shows these atypical cells lining the thin fibrovascular septae along with few rhabdomyoblast containing deeply eosinophilic material, concentrically arranged around the nucleus. Surrounding stroma is showing fibrosis and infiltration by chronic inflammatory infiltrates comprising of lymphocytes and few plasma cells admixed with blood vessels.

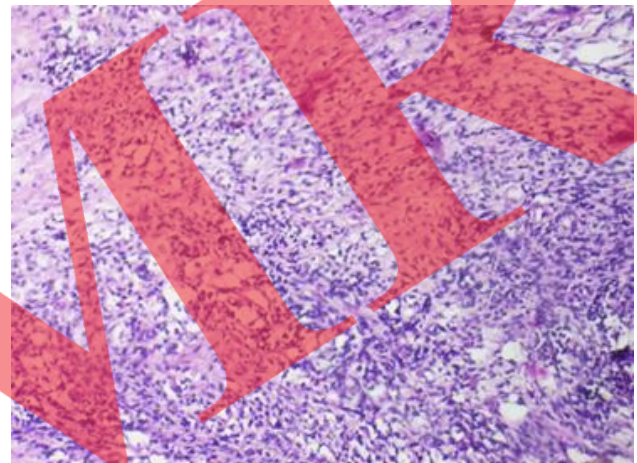


Fig 4a Microphotograph showing tumor composed of sheets of round to spindle shaped atypical cells have pleomorphic hyperchromatic nuclei, scant eosinophilic cytoplasm(H&E,100X)

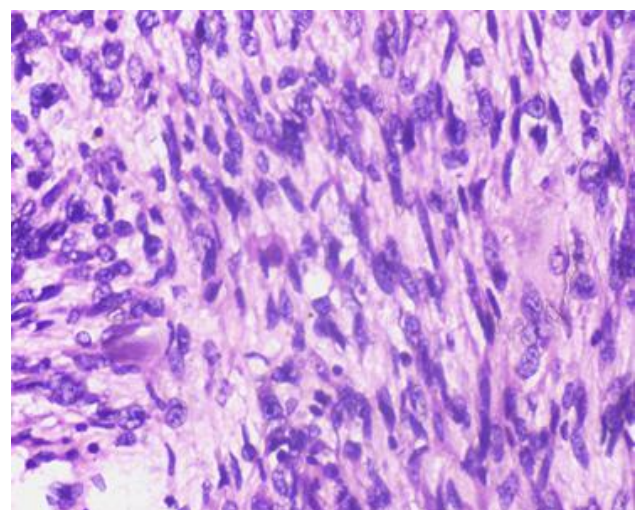


Fig 4 b, Microphotograph showing Rhabdomyoblast containing deeply eosinophilic material concentrically arranged around the nucleus.(H&E,400X)

DISCUSSION

Testicular sarcomas constitutes only 1-2% of all testicular tumors. Intrascrotal sarcomas are traditionally separated into paratesticular and intratesticular tumors (6). Paratesticular sarcomas are mostly rhabdomyosarcoma, seen in children and intratesticular sarcomas are very rare mostly associated with germ cell tumor (6-7). The origin of intratesticular rhabdomyosarcoma is believed to be teratomatous with rhabdomyoblastic overgrowth of primitive germ cells (6). The tumor derives from mesenchymal elements of testis envelope, epididymis and spermatic cord. Rhabdomyosarcoma is regarded as highly malignant tumor with frequent recurrence and dissemination via bloodstream and lymphatics (8). Metastasis of rhabdomyosarcoma is common to lungs, bone marrow, brain, liver, omentum and lymph nodes (9). The accurate diagnosis of sarcomatous component in germ cell tumor is very important because of implications of therapy. Immunohistochemistry is helpful to exclude other intratesticular spindle cell sarcomas like fibrosarcoma and leiomyosarcomas (10-11). Myogenin and MyoD1 are important IHC markers which aid in the confirmation of RMS. These IHC markers could not be done in the index case due to unavailability.

CONCLUSION

Primary intratesticular rhabdomyosarcoma is very rare, have aggressive growth pattern. Radical orchidectomy with negative surgical margins. The optimal management of paratesticular rhabdomyosarcoma remains unclear because of the rarity of the disease in adults. Radical orchidectomy with negative surgical margins followed by RPLND and chemotherapy is the recommended treatment. For the control of local recurrence and metastasis radiotherapy is recommended.

REFERENCES

1. Chigurupati R, Alfatooni A, Myall RW, Hawkins D, Oda D. Orofacial rhabdomyosarcoma in

neonates and young children: A review of literature and management of four cases. *Oral Oncol* 2002;38:508-15.

2. Duraes GV, Jham BC, Mesquita AT, dos Santos CR, Miranda JL. Oral embryonal rhabdomyosarcoma in a child: A case report with immunohistochemical analysis. *Oral Oncol Extra* 2006;42:105-8.
3. Wiss K, Solomon AR, Raimer SS, Lobe TE, Gourley W, Headington JT. Rhabdomyosarcoma presenting as a cutaneous nodule. *Arch Dermatol* 1988;124:1687-90.
5. Manasseh AN, Echejoh GO, Silas OA, Tanko MN, Jegede SK, Mandong BM. Testicular embryonal rhabdomyosarcoma: A case Report. *Int J Med Med Sci* 2009;1:470-2.
6. Zukerberg LR, Young RH. Primary testicular leiomyosarcoma: A report of two cases. *Hum Pathol* 1990;21:932-5.
7. Sefa R, Nazan O, Sevgi B, Ali OK, Bulent A. Paratesticular Embryonal Rhabdomyosarcoma: Report of a Case. *Iran J Pediat* 2009;19:430-4.
8. Stewart LH, Lioe TF, Johnston SR. Thirty year review of intrascrotal rhabdomyosarcoma. *Br J Urol* 1991;68:418-20.
9. Singh R, Chandra A, O'Brien TS. Primary intratesticular leiomyosarcoma in a mixed race man: A case report. *J Clin Pathol* 2004;57:1319-20
10. Kumar R, Bharti S, Khosla D, Kapoor R. Long term survival in paratesticular rhabdomyosarcoma. *Clin Cancer Invest J* 2012;1:31-2.
11. Kumar R, Kapoor R, Khosla D, Kumar N, Ghoshal S, Mandal AK, *et al.* Paratesticular rhabdomyosarcoma in young adults: A tertiary care institute experience. *Indian J Urol* 2013;29:110-3.

