

## DIABETIC MACULAR EDEMA IN ASSOCIATION WITH DIABETIC RETINOPATHY IN PATIENTS OF TYPE 2 DIABETES MELLITUS

Luxmi Singh, Lubna Ahmed, Swati Yadav, Pragati Garg, B.B Lal

Department of Ophthalmology

Era's Lucknow Medical College & Hospital, Sarfarazganj Lucknow, U.P., India-226003

### ABSTRACT

Diabetic Retinopathy is an important cause of blindness with diabetic macular edema(DME) affecting 15% of patients 15yrs after diagnosis. The prevalence of diabetes mellitus(DM) is expected to approximately double globally between 2000 and 2030. The burden of DME is likely to increase as prevalence of DM is expected to rise by 50% globally, from 2000 to 2030. Therefore, is a major cause of concern. To study diabetic macular edema prevalence and pattern in association with severity of diabetic retinopathy in patients of type 2 diabetes mellitus. 300 patients with type 2 diabetes mellitus were included in an observational cross sectional study. Clinical assessment was done by recording Visual acuity by Snellen's drum test, slit lamp examination, direct and indirect ophthalmoscope, fundus examination with +90 D lens, Goldman applanation tonometry, gonioscopy, Cirrus SD-OCT macula and fundus photography. Among 600 eyes, prevalence of DME was 14.0% and 24.3% in NPDR and PDR eyes respectively. Statistically, this difference was not significant ( $p=0.226$ ). Among the categories of diabetic retinopathy, a significant increase in prevalence of DME was observed with increasing severity of NPDR ( $p<0.001$ ). Among 87 eyes with DME, the pattern of DME was 59.8% with diffuse retinal thickening, 21.8% with cystoids macular edema and 18.4% with serous retinal detachment. Prevalence of DME was more in NPDR group increasing with severity of NPDR. The prevalence of DME pattern of diffused retinal thickening was most followed by cystoid macular edema and serous retinal detachment among those with diabetic retinopathy.

**KEYWORDS:** Diabetes mellitus, prevalence, DME, Diabetic retinopathy.

### INTRODUCTION

Diabetic Retinopathy is an important cause of blindness and is a progressive disease affecting the integrity of the microscopic vessels found in the retina, broadly divided into two clinical stages: non proliferative (NPDR) and proliferative diabetic retinopathy (PDR). Diabetic macular edema(DME) affects 15% of patients 15yrs after diagnosis (1). The prevalence of diabetes mellitus(DM) overall is expected to approximately double globally between 2000 and 2030 (2). The burden of DME is likely to increase as prevalence of DM is expected to rise by 50% globally, from 2000 to 2030 (3). DME affects central vision and can lead to decline in vision ranging from slight visual blurring to blindness, substantially affecting independence and quality of life (4-5). Clinically Significant Macular Edema (CSME) is defined as observation of retinal thickness or hard exudates accompanied with retinal thickening within 500 $\mu$ m of the center of the macula or if a zone of one-disc area size of retinal thickness is seen within one-disc diameter of the center of the macula, as per the Early Treatment of Diabetic Retinopathy Study (ETDRS report number 7, 1991).

There is not enough literature establishing the prevalence of diabetic macular edema among those with diabetic retinopathy in patients of type 2 diabetes mellitus.

**Materials and methods:** It was an observational cross sectional study, including 300 prediagnosed type 2 diabetics, attending the ophthalmology OPD at Era University referred from Medicine OPD for fundus evaluation. Clinical examination included assessment of Visual acuity by Snellen's drum test, slit lamp examination, applanation tonometry, direct and indirect ophthalmoscope, fundus examination with +90 D lens, gonioscopy, fundus photography, Cirrus SD-OCT macula. The data was analyzed using Statistical Package for Social Sciences, version 15.0. For, categorical data Chi-square test was used whereas continuous data was analyzed using ANOVA and student "t"-test. Multi variate assessment was done using logistic regression. The confidence level of the study was kept at 95% and hence a "p" value less than 0.05 indicated a statistically significant association.

**Result:** Among 600 eyes, a total of 65 (10.8%) had no retinopathy, 37 (6.2%) had PDR – of these 18 (3%) were mild to moderate PDR, 13 (2.2%) were high risk PDR and remaining 6 (1%) were advanced diabetic

Received on : 16-05-2018

Accepted on : 25-05-2018

### Address for correspondence

**Dr. Luxmi Singh**

Department of Ophthalmology  
Era's Lucknow Medical College &  
Hospital, Lucknow - 226003  
Email: drluxmi@redigmail.com  
Contact no: +91-9369123042

eyes. 493 (82.2%) had NPDR - of these 225 (45.6%) had as minimal NPDR, 152 (25.3%) had mild NPDR (25.3%), 72 (12%) as moderate NPDR, (1.6%) 10 very severe NPDR 34 (5.7%) severe NPDR. Those which could not be assessed were a total of 5 (0.8%) eyes.

Among categories of diabetic retinopathy, a significant increase in prevalence of DME was observed with increasing severity of NPDR (p<0.001). The prevalence rates increased from 10.7% to 70% from minimal to very severe NPDR groups. Prevalence of DME among all diabetics was 24.3% in PDR and 14.0% in NPDR types respectively. This difference was statistically (p=0.226) insignificant.

The pattern of DME among DME eyes (n=87) was 59.8% (52) with diffuse retinal thickening, 18.4% (16) with serous retinal detachment, and 21.8% (19) with cystoids macular edema.

**DISCUSSION**

Diabetic Retinopathy is an important cause of blindness with diabetic macular edema (DME) affecting 15% of patients 15yrs after diagnosis (1). The prevalence of diabetes mellitus (DM) is expected to approximately double globally between 2000 and 2030 (2). The burden of DME is likely to increase as prevalence of DM by 50% globally (3). Therefore, is a major cause of concern.

The prevalence of diabetic macular edema among diabetic retinopathy patients- Wong *et al.* (2008) 7-16.3%. Wang FH *et al* 8(2009) Study from rural China-

12%. Yau *et al.* (2012) (9) - 7.48%. Ding and Wong (2012) (8)-10% in USA. Lee *et al.* (2015) metaanalysis- range from 1.4% to 33.3% in different studies. We found it to be 13% in diabetic eyes with retinopathy whereas the overall prevalence in diabetic eyes (n=600) 14.5%.

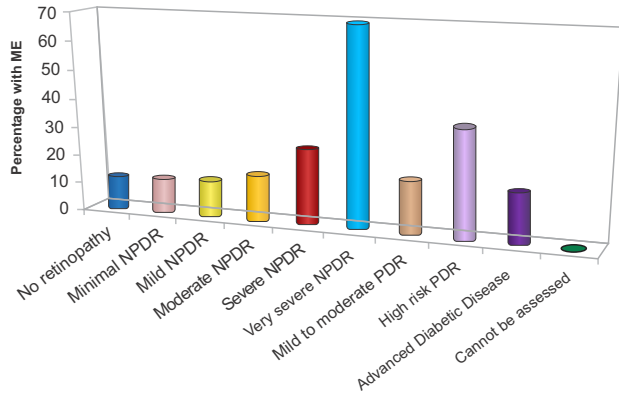
Prevalence of DME was 14.0% and 24.3% in NPDR and PDR types and 10.7% among those without retinopathy. No significant association of DME with different ETDRS categories of DR was seen. However, within NPDR subtype a significant association between severity of NPDR and DME was observed. The findings suggest that the regular course of diabetic retinopathy progression does not correlate with the course of diabetic macular edema progression.

Considering the pattern of DME amongst DR patients - 59.8% had diffuse retinal thickening followed by 21.8% having Cystoid macular edema and 18.4% having serous retinal detachment. Similar to results- Otani T *et al* (1999) (10), Cater A *et al* (2005) (11) Serous retinal detachment prevalence in series by Munk Mr *et al* (1999) (12) Ozdemir H *et al* (2005) varied from 15% to 31%. Cystoid macular edema pattern was slightly lower in our study as compared to the finding of Otani *et al.* (1999) (10) who reported it to be 47%. This differences in pattern findings to that of others could be attributed to the fact that we assigned only one pattern to an eye and included the dominating pattern. Whereas in some other studies 14 more than one patterns were identified and reported from a single eye.

SN	DR	Total No.	With DME (n=87)		Without DME (n=513)		Statistical Significance	
			No.	%	No.	%	$\chi^2$	'p'
1.	No retinopathy	65	7	10.7	56	86.15	0.025	0.874
2.	NPDR	493	71	14.4	424	86.0	0.567	0.452
	Minimal NPDR	225	24	10.7	201	89.3		
	Mild NPDR	152	18	11.8	134	88.2		
	Moderate NPDR	72	11	15.3	61	84.7		
	Severe NPDR	34	9	26.5	25	73.5		
	Very Severe NPDR	10	7	70.0	3	30.0	33.2	0.001

SN	DR	Total No.	With DME (n=87)		Without DME (n=513)		Statistical Significance	
			No.	%	No.	%	$\chi^2$	'p'
3.	PDR	37	9	24.3	28	75.7	3.07	0.08
4.	Mild to moderate PDR	18	3	16.7	15	83.3	2.18	0.337
	High risk PDR	13	5	38.5	8	61.5		
	Advanced Diabetic	6	1	16.7	5	83.3		
	Cannot be assessed	5	0	0	5	100		

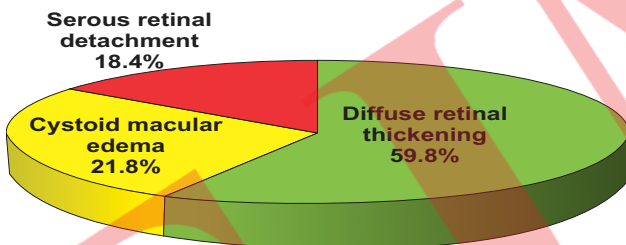
Table 1. Severity Diabetic Retinopathy (ETDRS) With Diabetic Macular Edema (n=600 eyes)



**Fig1: Diabetic macular edema Prevalence with Severity of diabetic retinopathy (n=600 eyes )**

SN	Characteristic	No. of Eyes	Percentage
1.	Diffuse retinal thickening	52	59.8
2.	Cystoid macular edema	19	21.8
3.	Serous retinal detachment	16	18.4

**Table 2: Patterns of DME (EDTR) in Diabetic Macular Edema Eyes (n=87eyes )**



**Fig2: Patterns of DME in DME Eyes (n=87eyes )**

**CONCLUSION**

No statistically significant correlation was established when DME was correlated with different EDTRS categories of diabetic retinopathy. However, DME prevalence showed increase with increase in grade of severity of NPDR. Occurance of diabetic macular edema is independent of diabetic retinopathy status of a diabetic eye.

The prevalence of DME pattern of diffused retinal thickening is the most with cystoids macular edema and serous retinal detachment following next, among eyes with diabetic retinopathy.

**REFERENCES**

1. Shaw Je, Sicree RA, Zimmet Pz. Global Estimates of the prevalence of diabetes for 2010 and 2030. Diabetes Res Clin Pract 2010;87:4-14.
2. Wild S. et al, Global Prevalence of diabetes: estimates for the year 2000 and projections for 2030. Diabetes Care 2004;27:1047-1053.
3. Chen E et al. Burden of illness of diabetic macular edema: literature review. Curr Med Res Opin 2010;28:1587-1597.
4. Hariprasad SM, Mieler WF, Grassi M, Green JL, Jager RD, et al. Vision-related quality of life in patients with diabetic macular edema. Br J Ophthalmol. 2008;92:89-92.
5. Lamoureux EL, Tai ES, Thumboo J, et al. Impact of diabetic retinopathy on vision-specific function. Ophthalmology. 2010;117:75-756.
6. Yang W, Lu J, Weng J et al. China National Diabetes and Metabolic Disorder Study Group. Prevalance of Diabetes among men and women in China. N Eng J Med 2010;362:1090-1101.
7. Wang FH, Liang YB, Zhang F, et al. Prevalance of diabetic retinopathy in rural China: the Handan Eye Study. Ophthalmology. 2009;116:461-67.
8. Lee R, Wong TY, Subanayagam C. Epidemiology of diabetic retinopathy, diabetic macular edema and related vision loss. Eye and vision 2015;2:17.
9. Otani T, Kishi S, Maruyama et al. Patterns of diabetic macular edema with OCT. Am J Ophthalmol. 1999;127:688-693.
10. Catier A, Tadayoni R, Paques M, et al. Characterisation of macular edema from various etiologies by OCT. Am J Ophthalmol. 2005;140:200-206.
11. Munk MR, Sac S, Huf W, et al. Differential diagnosis of macular edema of different pathophysiological origins by spectral domain OCT. Retina. 2014;34:2218-2232.
12. Ozdemir H, Karacorlu M, Karacorlus. Serous macular detachment in diabetic cystoids macular edema. Acta Ophthalmol Scan. 2005;83:63-66.



**How to cite this article :** Singh L., Ahmad L., Yadav S., Garg P., Lal B.B., Diabetic Macular Edema Association With Diabetic Retinopathy In Patients Of Type 2 Diabetes Mellitus. EJMR 2018;5(1):6-8.