

THE STUDY OF NUTRIENT FORAMEN OF BONES OF ARM AND FOREARM IN ADULTS

Anand Kumar Mishra, Sonia Jaiswal, P. K. Sharma, Vineeta Tewari

Department of Anatomy

Era's Lucknow Medical College & Hospital, Sarfarazganj Lucknow, U.P., India-226003

ABSTRACT

The variation in presence of number of nutrient foramen is important in long bones as nutrient foramen gives passage for entrance of nutrient arteries in to the bone. The present study was conducted on total 114 dry human long bones in department of anatomy, Era's lucknow medical college, lucknow. . The aim of the study was to determine the number of nutrient foramen in long bones of upper limb. Ethical approval was procured from the institutional ethical committee. In our study 97.40% humerus bones show single nutrient foramen, and 2.60% humerus bones show double NF, and all the radius and ulna show the single NF. The results of our study is similar with previous studies. The importance of knowledge about NF is very use full in orthopedic surgeries and in micro vascular bone grafting.

Received on : 27-03-2018

Accepted on : 21-05-2018

Address for correspondence

Dr. Sonia Jaiswal

Department of Anatomy

Era's Lucknow Medical College & Hospital, Lucknow, U.P., India-226003

Email: jaiswalsonia2008@gmail.com

Contact No: +91-9839020777

KEYWORDS: Nutrient Foramen, Humerus, Radius, Ulna

INTRODUCTION

Blood supply to the long bones in human body is by nutrient arteries, epiphyseal arteries, metaphyseal arteries and periosteal arteries. Among these arteries, nutrient arteries play a major role by supplying inner 2/3rd of cortex and whole medulla of the diaphysis (1-2).

Nutrient foramen is an opening into the bone shaft which gives passage to the blood vessels of the medullary cavity of a bone, for its nourishment and growth. It has been suggested that the direction of the nutrient foramina is determined by the growing end of the bone, which is supposed to grow at least twice as fast as the non-growing end. As a result, the nutrient vessels move away from the growing end of the bone (3). The position of nutrient foramina is constant during the growth of long bone (4). The position of nutrient foramina is variable and typical position of nutrient foramina can be determined after a study on human bones (5).

The topographical knowledge of these foramina is useful in certain operative procedures to preserve the circulation (6-7). Some bones such as femur and humerus have several nutrient foramina. Before entering the nutrient foramen the nutrient vessels become tortuous so that they will not affect the bone movement (8). Nutrient arteries play an important role during active growth period as well as uniting callus in fractured bone (9).

One or two main diaphyseal nutrient arteries enter the shaft obliquely through nutrient foramina leading into

nutrient canals. Their sites of entry are almost constant and characteristically directed away from the dominant growing epiphysis (10).

MATERIALS AND METHOD-

The study was conducted in total 114 (38 each) long bones of arm and forearm without any bias of age and sex, the material was collected from department of Anatomy, ELMC, Lucknow. The materials used were Hand lens, Hypodermic needle (26 gauge),

Nutrient foramen was observed in all bones by the naked eye and then with the help of hand lens.

OBSERVATIONS AND RESULTS

The number of nutrient foramen was observed according to its presence or absence. In most of the bones single nutrient foramen was observed and in some bones incidence of double foramen was also found.

Frequency of NF

		Crosstab				Total
		Type				
		HUMERUS	RADIUS	ULNA		
Frequency of NF	1	Count	37	38	38	113
		% within type	97.4%	100.0%	100.0%	99.1%
	2	Count	1	0	0	1
		% within type	2.6%	.0%	.0%	.9%
Total		Count	38	38	38	114
		% within type	100.0%	100.0%	100.0%	100.0%

Table. 1 showing the percentage of frequency of NF

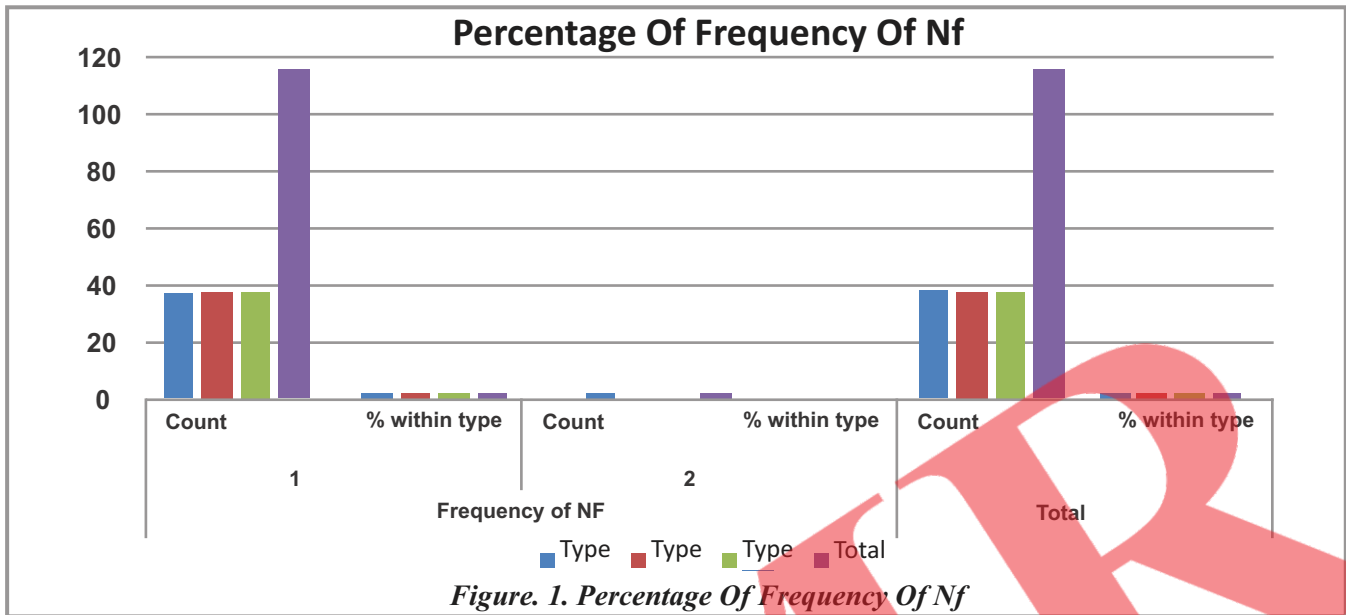


Figure. 2. Diagram showing nutrient foramen -

In humerus (37 bones) 97.4% bones have single nutrient foramen and only (1 bone) 2.6% bone has double nutrient foramen. While in case of radius (38 bones) 100% bones have single nutrient foramen. And all ulna (38 bones) 100% bones have single nutrient foramen.

DISCUSSION

In embryonic period all the nutrient arteries course caudally. This is true in hemodynamic point of view to force the blood from cephalic to caudal side. The direction of nutrient foramina in human long bones is directed away from the growing end. This is due to one end of long bone is growing faster than the other end (11).

Humerus is the largest bone of upper limb so it has highest vascularity among the bones of upper limb. Blood supply is mainly by brachial artery and also by axillary, radial and ulnar arteries. The periosteal and metaphyseal arteries supply the outer cortex and metaphysis of bone and the inner half of cortex and medulla depend upon nutrient artery for blood supply.

Vascularity of humerus was studied by Laing and he stated that nutrient artery of humerus must be protected during operations done on shaft of humerus (12)

Menck J et al. reported that the inner part of humerus is usually supplied by just one nutrient artery entering the nutrient foramen just below its middle part. In radius the artery arises from the anterior or posterior interosseous artery, this explains the foramina on its posterior surface. The ulna gets its nutrient artery from the ulnar artery or any of its muscular branches. In both radius and ulna, the main branch of the nutrient artery has an ascending course. The anterior interosseous artery, as the main artery of periosteal and end osteal supply of human ulna and radius, is important in transplantation and reconstruction, especially with a view to reduce the rate of pseudarthrosis. The nutrient arteries of the ulna and radius enter the bones in the second proximal quarter of diaphysis, at the radius from anterior to medial, at the ulna from anterior to antero-lateral (13).

Frequency of NF

In our study 97.40% humerus bones show single nutrient foramen, and 2.60% humerus bones show double NF, this findings is more similar the study was done by B. V. Murlimanju et al. in 2011, found presence of single NF in 93.8% humerus bones, and double NF in 3.1% humerus bones. In our study the frequency of occurrence of nutrient foramen in humerus is more or less similar as previous studies.

In our study all the radius and ulna bones show single nutrient foramen, and this results is also similar to study done by B.V. Murlimanju et al. in 2011, they also found that all radius show single nutrient foramen. In case of ulna the results of our study is exact same as previous study so our study is correlates with previous study.

Year	Studied by	Sample size	No. of NF
2018	Current study	114	97.4% H-1NF,2.6% H-2NF,100%R-1NF,100% U-1NF
2017	Arvind Kumar Pankaj et al. (14)	350	80.86% -1NF,13.42%-2 NF,0.29% -3 NF 5.43% -Absent
2016	Asharani S K et al.(15)	120	87% -1 NF 11% - 2 NF
2016	Guthi Reddy et al.(16)	104	96.3% R -1 NF,3.7% R-2NF 100% U -1NF
2015	Satish M. Patel et al.(17)	120	66% H -1NF,68% R -1 NF 78% U -1NF
2015	Mansur DI et al.(18)	253	60.87%H-1 NF,28.85% H-2NF,6.32% H - 3NF,1.98% H-4NF,1.9%H-Absent
2014	KS Solanke et al.(19)	260	4% H -Absent,5% R -Absent,3.75% U-Absent 4% H-2 NF,2.5% R-2 NF

Table. 2. Comparison of frequency of nutrient foramen with previous studies

CONCLUSION

Total one hundred fourteen long bones of upper limb i.e. thirty eight each of the Humerus, Radius and ulna was taken from Department of Anatomy, Era's Lucknow Medical College Lucknow, and was studied for the number of Nutrient foramen. It was found that double nutrient foramen was found in one case of humerus, and all the radius and ulna show only one nutrient foramen.

This anatomical study of nutrient foramina in shaft of long bones is of paramount importance considering its medico-legal aspect. It is also important for surgical procedures like bone grafting and micro surgical bone transplantation.

REFERENCES

1. Gray's Anatomy. The anatomical basis of clinical practice. Standring S, Healy JC, Johnson D, Collins P, et al, London: Elsevier Churchill Livingstone 2005;40th ed:871. 2
2. Principles of general anatomy. Asim Kumar Dutta, the Blood supply of bones 2013;7th ed:58,75,76.
3. Malukar O, Joshi H. Diaphysial Nutrient Foramina In Long Bones And Miniature Long Bones, NJIRM; 2011, 2 (2): 23-26
4. Harris, H. A. 1933. Bone Growth in Health and Disease. London, Humphrey Milford; 59(2): 265-267
5. LutkenPoul. 1950. Investigation into position of nutrient foramen & direction of the vessel canals in the shaft of the humerus and femur in man. Acta. Anat., 9: 57-68
6. Mysorekar VR. Diaphyseal Nutrient Foramina in human long bones. Journal of Anat 1967;101(4):813-822.
7. McKee NH, Haw P, Vettese T. Anatomic study of nutrient foramen in the shaft of Fobula. ClinOrthopRelat Res. 1984;1
8. Singh V. Skeleton. In: Textbook of Anatomy. 1st edition. New Delhi: Elsevier, 2008;80
9. Standring S. Functional anatomy of the musculoskeletal system. Gray's Anatomy. The Anatomical basis of clinical practice. 40th edition. London: Churchill Livingstone Elsevier, 2008;91
10. Standring Susan. Gray's Anatomy- The Anatomical Basis of Clinical Practice. Functional anatomy of the muscular system. 39th edition, Elsevier Churchill Livingstone. Edinburgh, London; 2005: p 95
11. Bichitrananda Roul and Meena Goyal, a study of nutrient foramen in long bones of superior extremity in human being, International Journal of Current Research in Life Sciences 2015;4(4):198-200.
12. Sabah Yaseen, Morphological and Topographical Study of Nutrient Foramina in Adult Humerii, international journal of innovative research & development, 2014; 1(3),
13. B. V. Murlimanju, K. U. Prashanth, Latha V. Prabhu, Vasudha V. Saralaya, Mangala M. Pai, Rajalakshmi Rai, Morphological and topographical anatomy of nutrient foramina in human upper limb long bones and their surgical importance, Rom J MorpholEmbryol 2011, 52(3):859-862

14. Arvind Kumar Pankaj,, Rakesh Kumar Verma, Archana Rani, Anita Rani, Navneet Kumar, Morphometric study of nutrient foramina of humerus in North Indian population Indian Journal of Clinical Anatomy and Physiology, April-June, 2017;4(2):169-172
15. Asharani S K, Ajay Ningaiah. A study on the nutrient foramen of humerus. Int J Anat Res 2016;4(3):2706-2709.
16. Guthi Reddy, Manoj Kumar Reddy, C. Siddaramulu, Arun Kumar S. Bilodi, morphometric study of the nutrient foramina of unknown radius and ulna and their clinical importance in the region of kadapa [rayalaseema], andhra pradesh , Journal of evidence based medicine and healthcare 2016: 27(3): 1222-1229.
17. Dr. Satish M. Patel, Dr. Rakesh K.Vora, Dr. Badal M.Jotania, A Study Of Diaphyseal Nutrient Foramina In Human Lower Limb Long Bones, Natl J Integr Res Med. 2015; 6(3): 14-18
18. Mansur DI, Manandhar P, Haque MK, Mehta DK, Duwal S, Timalsina B, A Study on Variations of Nutrient Foramen of Humerus with its Clinical Implications, Kathmandu University Medical Journal, 2015; 14(53):78-83 15.
19. Solanke KS, Bhatnagar R, Pokhrel R. Number and position of nutrient foramina in humerus, radius and ulna of human dry bones of Indian origin withclinical correlation. OA Anatomy 2014;2(1):01-4.

