

UTERINE LIPOLEIOMYOMA : A RARE CASE REPORT

Renu Sahay, Madhu Singh

Department of Pathology

MLB Medical College, Jhansi, U.P., India-284001.

Received on : 29-06-2024

Accepted on : 29-10-2024

ABSTRACT

Uterine lipoleiomyoma and pure lipomas are both benign tumors of fatty tissue. They are uncommon, with a reported incidence of only 0.03% to 0.25%. Pure cervical lipomas are especially rare. While MRI can sometimes help identify the fatty nature of these tumors before surgery, most are diagnosed after surgery by examining the tissue under a microscope. Despite several proposed theories, the exact origin and development of these tumors remain a mystery. Uterine lipoleiomyomas are a specific type of uterine leiomyoma (fibroids) distinguished by the presence of fatty tissue. They have the potential to continue growing even after menopause. We present the case of a patient diagnosed with a uterine lipoleiomyoma through ultrasound and CECT imaging, which was later confirmed through tissue analysis. Currently, surgical intervention remains the primary treatment approach for managing lipoleiomyomas.

KEYWORDS: Lipoleiomyoma, Smooth muscle, Histogenesis, Fibroids.

INTRODUCTION

Uterine lipomas, first identified by Lobstein in 1816, fall into two distinct categories: "pure lipomas," consisting solely of fatty tissue, and "mixed lipomas," which also contain muscle tissue (1). Lipoleiomyomas, composed of both fatty tissue and smooth muscle cells (SMCs), are often categorized as "mixed lipomas", were first described in 1965 (2). This distinct type of tumor was characterized by its composition of diverse proportions of fatty tissue and SMCs (2-3). A uterine lipoleiomyoma is an uncommon variation of the more prevalent uterine leiomyoma (4). Lipoleiomyomas are rare, benign tumors characterized by a mixture of mature fat cells (adipocytes) and SMCs.

The initial research by Willén et al. in 1978 estimated that lipoleiomyomas occur in roughly 0.03% to 0.2% of all uterine leiomyomas (3), a more recent study by Akbulut et al. in 2014 suggested a notably higher incidence of 2.9% (5). This latter study also found that over 80% of lipoleiomyomas occurred in women who have gone through menopause, with an average age of 55.5 years (5). Furthermore, lipoleiomyoma has been identified as the predominant variant in postmenopausal women with uterine leiomyomas, accounting for 85.7% of cases in one study (6).

Address for correspondence

Dr. Madhu Singh

Department of Pathology

MLB Medical College, Jhansi,

U.P., India-284001.

Email: singhmadhu2404@gmail.com

Contact no: +91-7905366390

The patients in the study were either parous (had given birth) or nulliparous (had not given birth), but none were pregnant at the time (5). With the increasing global population and the aging demographic, the number of lipoleiomyoma cases is expected to rise, though the condition itself rarely leads to death.

The origin of lipoleiomyomas remains a subject of investigation, but it is hypothesized that these tumors arise through one of two potential pathways: the first involves the direct transformation of existing SMCs within the uterus, whereby these cells undergo a phenotypic change and begin to accumulate fatty tissue. The second proposed pathway involves the differentiation of multipotent mesenchymal cells, which possess the capacity to develop into various cell types, into adipocytes (fat cells) within the uterine tissue (7). Additionally, decreasing estrogen levels following menopause seem to be a significant contributing factor (7). The development of a lipoleiomyoma could occur **concurrently** with the formation of a leiomyoma (8), through the fatty transformation of an existing leiomyoma (9), or as a new growth within the uterine muscle layer (myometrium).

Even though numerous theories have been proposed regarding the origin and development of these tumors, their exact histogenesis remains elusive (10). The

significance of these uterine wall lesions lies in the potential for concurrent malignancies in the ovaries, fallopian tubes, or uterus. Additionally, patients with these lesions may also present with other metabolic disorders and abnormal estrogen levels (11).

This report aims to present a case of uterine lipoleiomyoma, detailing the patient's journey from initial symptoms and presentation through diagnosis and subsequent management.

CASE REPORT

A 42-year-old woman visited the surgery department due to abdominal lump, discomfort, and pain. She did not report any burning sensation while urinating, vaginal discharge, vaginal bleeding, difficulty urinating, changes in bowel habits, or general symptoms of illness. Additionally, There was no reported history of cancer within the family. Upon physical assessment, a 10x10cm lump was detected in her pelvic region. Her medical history was otherwise largely unremarkable. An abdominal and pelvic ultrasound revealed a large, hyper-echoic mass measuring 10.7x13.2x11.1cm in the pelvic cavity, extending above the navel. The imaging also showed an enlarged uterus with a thickened endometrium, fibroids, and an enlarged cervix.

A Contrast-Enhanced Computed Tomography (CECT) scan of the abdomen endorsed a large, varied mass in the pelvic area, displacing the uterus forward and compressing its lower right side. The mass measured approximately 156x148mm. The imaging also showed swelling in the right kidney due to a blocked ureter. Routine blood tests, including HbA1c (for diabetes) and CA125 (a tumor marker), were normal. The patient had a surgical procedure to remove her uterus, both fallopian tubes, and ovaries. The pathology report after surgery described the removed uterus as measuring 6.5x5.5x5cm, with the cervix appearing to have been surgically removed.

Upon cutting, the uterus revealed a grayish-white surface with a fibroid measuring 4cm in diameter. The endometrial cavity was narrow. A large growth, measuring 15x13x7cm, was attached to the uterus. When cut, it showed a grayish-white surface with areas of bleeding. Both ovaries and fallopian tubes appeared normal when examined.

Under the microscope, the tumor was found to be made up of bundles of smooth muscle fibers mixed with mature fat cells. The SMCs tested positive for vimentin and desmin, while the fat cells were positive for estrogen receptor (ER), and progesterone receptor (PR).



Fig. 1: Gross Appearance

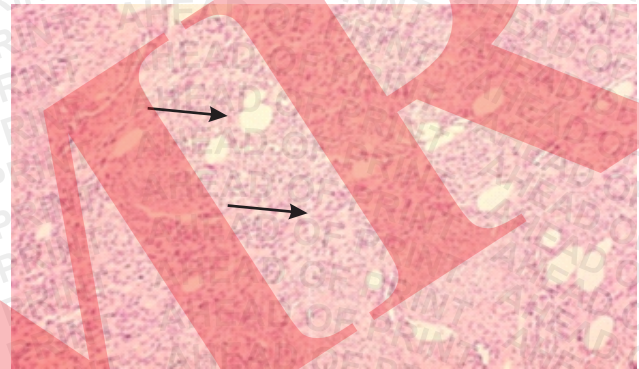


Fig. 2: Smooth Muscle Cells Proliferation Admixed with Mature Adipocytes in Lipoleiomyoma (H&E 10X)

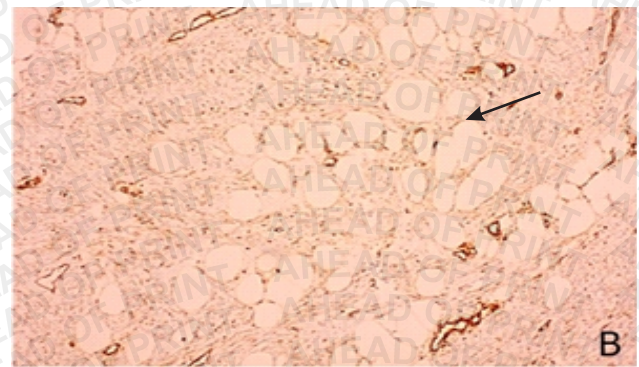
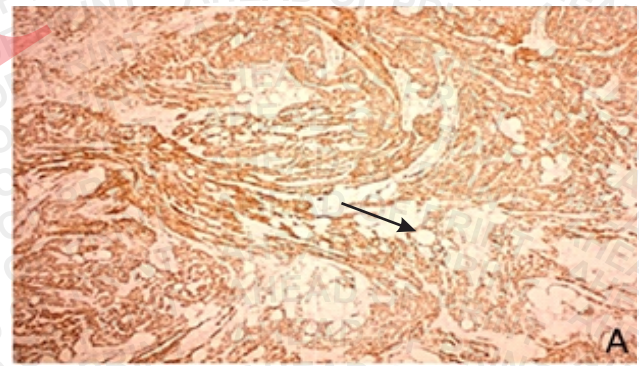


Fig. 3: (A) Desmin Positive A (4X) (B) Vimentin Positive (10X)

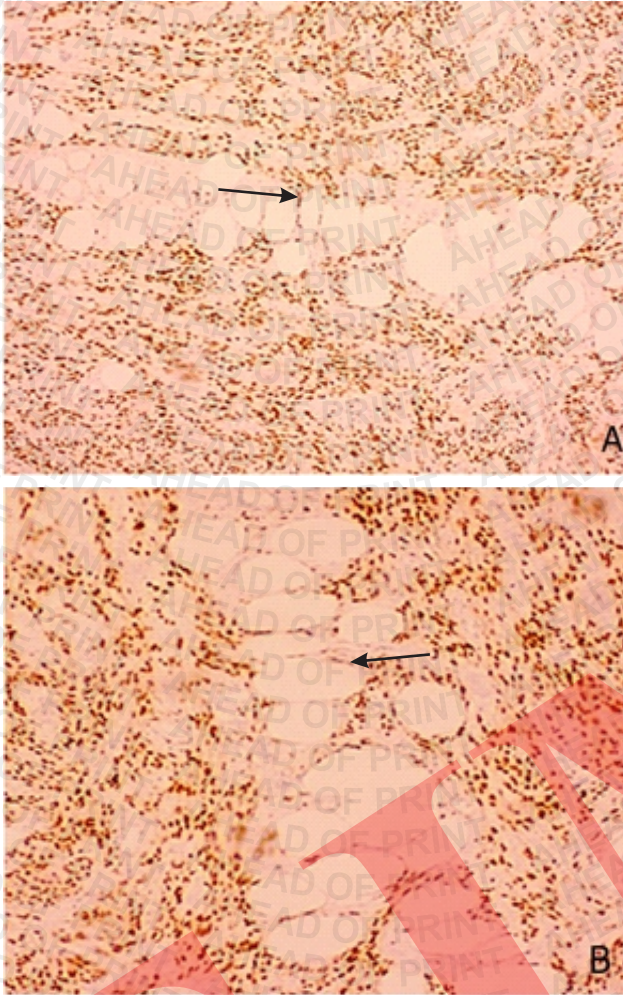


Fig. 4: (A) PR positive (10X) (B) ER positive (10X)

DISCUSSION

Lipoleiomyomas are a type of uterine fibroid that contain fatty tissue. They are usually discovered incidentally and most often affect postmenopausal women. Uterine lipoleiomyoma, a non-cancerous growth composed of fat cells within the uterus, is uncommon, accounting for only 0.35% of uterine myomatous tumors (12). It is typically found in the women after menopause and often presents similarly to uterine leiomyomas (12).

Lipoleiomyomas, while generally benign, can cause complications due to their size and pressure on surrounding structures. As they primarily occur in women over 50, fertility is usually not a concern. The choice of treatment for a uterine lipoma is influenced by factors such as the tumor's size, any associated symptoms experienced by the patient, and their general health condition.

For asymptomatic patients with a suspected lipoleiomyoma, management may be similar to that

for conventional leiomyomas, often involving observation only. However, because a definitive diagnosis cannot be made before surgery, a needle biopsy guided by ultrasound can be crucial for confirming the diagnosis.

Under a microscope, these tumors show a mix of SMCs, mature adipocytes, and fibrous tissue. This composition likely results from the transformation of SMCs within leiomyomas into mature adipocytes (13).

While lipoleiomyomas are primarily found in the uterus, they have also been identified in other pelvic locations like the cervix, broad ligament, retroperitoneum, and ovary [14]. The differential diagnosis for fatty pelvic masses in females includes benign cystic ovarian teratomas, other lipomatous ovarian tumors, pelvic lipomas, and liposarcomas in addition to uterine lipoleiomyomas [14-15]. Lipoleiomyomas are widely considered benign tumors that do not impact mortality rates [15].

Although histopathological analysis provides the definitive diagnosis, radiological investigations are crucial for pre-operative identification and localization of lipoleiomyomas. Additionally, immunohistochemical (IHC) studies have contributed significantly to our understanding of their intricate origin. Mignogna et al. reported that fat cells in these tumors react with vimentin, desmin, and SMA antibodies, supporting the theory of smooth muscle cells transforming directly into fat cells. In our case, mature adipocytes also showed immunoreactivity with vimentin and desmin (16). Similar findings were observed in a study by Sharma and Mandal (17). Cytogenetic studies of uterine lipoleiomyoma further suggest that their development is similar to that of typical leiomyomas (17).

Researchers suggest that elevated estrogen levels, often associated with metabolic disorders like hyperlipidemia, hypothyroidism, diabetes mellitus, postmenopausal lipid changes, and pregnancy-related toxemia, may contribute to lipoleiomyoma development (17-18). These estrogen elevations, along with menopause-related lipid metabolism changes, could be key factors, as patients often present with conditions like hypothyroidism, hyperlipidemia, and diabetes (19-20).

Lipoleiomyomas frequently affect postmenopausal women (19-22), who may experience no symptoms or present with symptoms resembling those of uterine leiomyomas, including vaginal bleeding, pain in abdomen, abdominal lump and increased urinary frequency. These tumors typically show up as single,

enlarged masses of different sizes, most often found in the main part of the uterus. However, they have also been seen in the cervix, broad ligament, area behind the abdomen (retroperitoneum), and ovaries (23).

Asymptomatic uterine lipoleiomyomas, being benign, can often be managed conservatively. Accurate diagnosis and differentiation from other adipocytic pelvic tumors are crucial to avoid unnecessary surgical intervention (24). Treatment generally depends on the patient's the size of the mass and symptoms. In symptomatic patients with large lipoleiomyomas, medical management with pain medications and hormone therapy may help alleviate symptoms.

In this case study, the patient was a 43-year-old woman with no notable medical history or lab results suggesting any metabolic disorders. While a few studies have reported coexisting gynecological malignancies in patients with lipoleiomyomas (18, 25), our patient underwent a total hysterectomy and no evidence of gynecological malignancy was found.

CONCLUSION

Lipoleiomyoma, an elusive and benign uterine tumor, often masquerades as its more common counterpart, the leiomyoma, making clinical distinction a formidable challenge. However, the discerning eye can suspect its presence in postmenopausal women presenting with a distinctive hyperechoic uterine lesion framed by a hypoechoic rim. The final verdict, however, rests solely with the pathologist's microscope. This case report underscores the rarity of this entity, particularly its manifestation at a relatively young age, adding a compelling layer to the existing medical literature.

PATIENT CONSENT

Prior to initiating this report, we secured written informed consent from the patient for the publication of their case details.

REFERENCES

1. Brandfass RT, Everts-Suarez EA. Lipomatous tumors of the uterus: a review of the world's literature with report of a case of true lipoma. *American journal of obstetrics and gynecology*. 1955; 70(2): 359-367.
2. Jacobs DS, Cohen H, Johnson JS. Lipoleiomyomas of the uterus. *American Journal of Clinical Pathology*. 1965; 44(1): 45-51.
3. R. Will'en, A. Gad, H. Will'en, Lipomatous lesions of the uterus, *Virchows Arch. A Pathol. Anat. Histol*. 1978; 377: 351-361.
4. Karaman E, Çim N, Bulut G, et al. A case of giant

- uterine lipoleiomyoma simulating malignancy. *Case Rep Obstet Gynecol*. 2015; 2015: 926961.
5. M. Akbulut, M. Gundogan, A. Yorukoglu, Clinical and pathological features of lipoleiomyoma of the uterine corpus: a review of 76 cases, *Balk. Med J*. 2014; 31: 224-229.
6. Y. Oi, K. Katayama, G. Hirata, et al., Significance of postmenopausal uterine leiomyomas: focus on variants. *J. Obstet. Gynaecol. Res*. 2018; 44: 1445-1450.
7. S.G.S. Khandeparkar, S. Deshmukh, P.D. Bhayekar, A rare case of lipoleiomyoma of the vulva: cytological and immunohistopathological study. *J. life Health*. 2013; 4: 238-240.
8. W. Siei'nski, Lipomatous neometaplasia of the uterus. Report of 11 cases with discussion of histogenesis and pathogenesis. *Int. J. Gynecol. Pathol. Off. J. Int. Soc. Gynecol. Pathol*. 1989; 8: 357-363.
9. M. Lin, J. Hanai, Atypical lipoleiomyoma of the uterus, *Pathol. Int*. 1991; 41: 164-169.
10. Vamseedhar A, Shivalingappa DB, Suresh DR, et al. Primary pure uterine lipoma: A rare case report with review of literature. *Indian J. Cancer*. 2011; 48: 385-387.
11. Salman MC, Atak Z, Usubutun A, et al. Lipoleiomyoma of broad ligament mimicking ovarian cancer in a postmenopausal patient: Case report and literature review. *J. Gynecol Oncol*. 2010; 21: 62-64.
12. Aung T, Goto M, Nomoto M, et al. Uterine lipoleiomyoma: a histopathological review of 17 cases. *Pathol. Int*. 2004; 54: 751-758.
13. Avritscher R, Iyer RB, Ro J, et al. Lipoleiomyoma of the uterus. *AJR Am J Roentgenol*. 2001; 177: 856.
14. Kumar S., Garg S., Rana P., et al. Lipoleiomyoma of uterus: uncommon incidental finding. *Gynecol Obstet*. 2013; 3: 145.
15. Manjunatha HK, Ramaswamy AS, Kumar BS, et al. Lipoleiomyoma of uterus in a postmenopausal woman. *J. Midlife Health* 2010; 1: 86-88.
16. Mignogna C, Di Spiezio Sardo A, Spinelli M, et al. A case of pure uterine lipoma: Immunohistochemical and ultrastructural focus. *Arch Gynecol Obstet*. 2009; 280: 1071-1074.
17. Sharma S., Mandal A.K. Uterine lipoleiomyoma: A five year clinicopathological study. *Ann Woman Child Health*. 2016; 2: A22-A26.

18. Salman MC, Atak Z, Usubutun A, et al. Lipoleiomyoma of broad ligament mimicking ovarian cancer in a postmenopausal patient: Case report and literature review. *J Gynecol Oncol.* 2010;21: 62-64.
19. Nayal B, Somal PK, Rao AC, et al. Uterine lipoleiomyoma: A case report of a rare entity. *Int J Appl Basic Med Res.* 2016; 6: 134-136.
20. Krenning RA, De Goey WB. Uterine lipomas. Review of the literature. *Clin Exp Obstet Gynecol.* 1983; 10: 91-94.
21. Chawla A, Rathod K, Raut A, et al. Uterine lipoleiomyoma: Radiological case of the month. *Medscape.* 2004;33: 45-48.
22. Oppenheimer DA, Carroll BA, Young SW. Lipoleiomyoma of the uterus. *J Comput Assist Tomogr.* 1982; 6: 640-642.
23. Kumar S, Garg S, Rana P, et al. Lipoleiomyoma of uterus: Uncommon incidental finding. *Gynecol Obstet.* 2013; 3: 145.
24. Dodd GD, Budzik RF. Lipomatous uterine tumors: Diagnosis by ultrasound, CT, and MR. *J Comput Assist Tomogr.* 1990; 14: 629-632.
25. Wang X, Kumar D, Seidman JD. Uterine lipoleiomyomas: A clinicopathologic study of 50 cases. *Int J Gynecol Pathol.* 2006; 25: 239-242.

Orcid ID:Renu Sahay - <https://orcid.org/0009-0008-1341-9587>Madhu Singh - <https://orcid.org/0009-5845-1187>**How to cite this article:**Sahay R., Singh M. Uterine Lipoleiomyoma : A Rare Case Report. *Era J. Med. Res.* 2024; 11(2): 1-5.**Licencing Information**Attribution-ShareAlike 2.0 Generic (CC BY-SA 2.0) Derived from the licencing format of creative commons & creative commons may be contacted at <https://creativecommons.org/> for further details.