

EVALUATION OF CAROTID ARTERIAL SYSTEM IN STROKE PATIENTS USING COLOUR DOPPLER SONOGRAPHY IN A TERTIARY CARE INSTITUTE

Kanika Malhotra, Lavan Saxena, Ganesh Kumar, Abhishek Agrawal, Zeeshan Siddiqui

Department of Radiodiagnosis

Integral Institute of Medical Sciences and Research, Lucknow, U.P., India - 226026

Received on : xx-xx-xxxx

Accepted on : xx-xx-xxxx

Address for correspondence

Dr. Kanika Malhotra

Department of Radiodiagnosis

Integral Institute of Medical Sciences and Research, Lucknow, U.P., India - 226026

Email: drkanikamalhotra102@gmail.com

Contact no: +91-7876944111

ABSTRACT

Stroke ranks among the world's major causes of mortality and disability, often linked to carotid artery atherosclerosis. Non-invasive imaging techniques such as colour Doppler sonography provide valuable insights into the carotid arterial system. To assess the carotid artery system in stroke patients with colour Doppler sonography, with an emphasis on carotid stenosis, plaque morphology, and intima-media thickness (IMT). This observational research included 50 stroke patients from a tertiary care hospital. Colour Doppler sonography was performed to measure IMT, Assess the degree of carotid stenosis and categorise the structure of the plaque. Majority of carotid arteries had <50% stenosis. Older age linked to greater stenosis and IMT. Color Doppler imaging is effective for screening carotid artery disease. Colour Doppler sonography is an effective tool for non-invasive evaluation of carotid arterial system, aiding in early detection and management of carotid artery disease.

KEYWORDS: Carotid Arterial System, Stroke, Colour Doppler Sonography, Carotid Stenosis, Plaque Morphology.

INTRODUCTION Stroke represents a major global health issue, resulting in considerable illness and death. Ischemic strokes make up about 80–85% of all strokes, and carotid artery stenosis is an important contributing risk factor (1). Narrowing of the carotid arteries, primarily because of atherosclerosis, can lead to diminished cerebral blood flow and increase likelihood of thromboembolic events (2). Accurate and prompt assessment of the carotid arteries is crucial for effective management, and prevention of stroke. Colour Doppler sonography has emerged as a reliable, non-invasive imaging technique for assessing carotid artery stenosis. It offers real-time visualization of blood flow and vessel wall abnormalities, making it a valuable tool in the clinical evaluation of stroke patients (3). Among the primary causes of death and morbidity is stroke. 80–85% of fall strokes are due to ischemic infarcts. One of the primary risk factors for ischemic stroke, which accounts for 5–10% of cases, is carotid atherosclerosis (4). It has been demonstrated that carotid endarterectomy significantly lowers the risk of stroke in patients with substantial stenosis, or 70% or higher.

Plaque composition is thought to play a significant role in symptom determination. Thus, a trustworthy,

ideally non-invasive technique to describe the content and structure of the plaque would be helpful in identifying patients who are more susceptible to plaque disruption and in identifying the factors that contribute to the formation of unstable atherosclerotic lesions. A variety of sonographic techniques have been utilized for over ten years to examine carotid arteries in patients with cerebrovascular illness.

This study aims to assess the carotid arterial system using colour Doppler sonography in stroke patients admitted to a tertiary care hospital.

AIMS AND OBJECTIVES

The objective of this study is to evaluate carotid arterial system using colour Doppler sonography in stroke patients. The specific objectives include:

- Evaluating the prevalence of carotid artery stenosis in patients with stroke.
- Analyzing the affiliation between carotid artery stenosis and patient demographics such as age and gender.
- Evaluating the efficacy of colour Doppler sonography in detecting carotid artery abnormalities.

REVIEW OF LITERATURE

Carotid artery disease has been widely studied due to its significant role in cerebrovascular events. Carotid sonography has been demonstrated as an effective tool in detecting stenosis and assessing stroke risk (5). Research has demonstrated that the existence of plaques in the carotid arteries, particularly those causing significant luminal narrowing, has been linked to a higher risk of stroke (6).

Development of colour Doppler sonography has enhanced the ability to evaluate both the structural and hemodynamic aspects of the carotid arteries. It allows for the measurement of intima-media thickness (IMT) and the detection of turbulent flow, both of which are indicators of atherosclerotic disease (7). Previous research has highlighted the utility of this imaging modality in routine stroke care, emphasizing its role in both diagnosis and follow-up (8).

MATERIAL AND METHODS

Study Design

This cross-sectional investigation was carried out at the Department of Radiodiagnosis, IIMS&R, Lucknow. The institutional review board granted ethical approval.

STUDY POPULATION

The study involved the enrolment of a total of [50] patients who had been diagnosed with stroke. The inclusion criteria was patients with confirmed ischemic stroke, while exclusion criteria included patients with a history of carotid surgery or incomplete medical records.

DATA COLLECTION

All patients underwent a detailed clinical examination followed by colour Doppler sonography of the carotid arteries. The sonographic evaluation was performed using [Aloka Hitachi F 31 Ultrasound and Doppler machine], and images were analyzed for the presence of stenosis, plaque morphology, and IMT.

STATISTICAL ANALYSIS

[SPSS version 24.0 (IBM Corp, Armonk, NY, USA)] used to analyse the data. The sonographic results and patient data were compiled using descriptive statistics. Using logistic regression analysis and chi-square testing, the prevalence of carotid artery stenosis was determined along with its correlation with demographic characteristics.

Observations and Results

- **Demographics:** 50 patients (72% male, 28% female), mainly 60-69 years.
- **Plaque Detection:** 71 out of 100 arteries had plaques.

- **Types:** 39.43% hypoechoic, 21.13% hyperechoic, 39.43% calcified.
- **Surface:** 15.49% irregular, 84.5% smooth.
- **Plaque Morphology:** Irregular plaques were mostly calcified (72.72%). Smooth plaques: 43.33% homogeneously hypoechoic, 33.33% calcified.
- **Stenosis Severity:** 73.2% <50%, 12.7% 50-59%, 5.6% 60-69%. More prevalent on the left (52.1%). Males more likely to have <50% stenosis (p < 0.01).
- **Hemodynamics:** Higher stenosis associated with increased ICA velocities.
- **IMT:** 48% had IMT >0.80mm; 29.16% under 60 years, 70.84% over 60 years.

STATISTICAL ANALYSIS

We found statistically significant association among carotid artery stenosis and male gender (p < 0.05). Additionally, age was found to be a significant predictor of stenosis severity (p < 0.01).

OBSERVATIONS AND RESULTS

Gender	No. of Patients	Percent
Female	14	28.00%
Male	36	72.00%
Total	50	100.00%

Table 1: Gender Distribution

Age (Years)	No. of cases	Percentage
30-39	1	2.00%
40-49	3	6.00%
50-59	10	20.00%
60-69	18	36.00%
70-79	13	26.00%
80-89	4	8.00%
90-99	1	2.00%
Total	50	100.00%

Table 2: Age Distribution

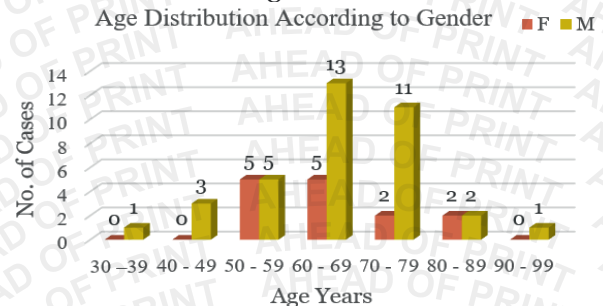


Fig. 1: Age Distribution of the Patients According to Gender

Plaque surface	Calcified	Heterogeneously hyperechoic	Heterogeneously hypoechoic	Homogeneously hyperechoic	Homogeneously hypoechoic	Not seen	%
Irregular	8	2	1	0	0	0	11.0%
Not seen	0	0	0	0	0	29	29.0%
Smooth	20	7	1	6	26	0	60.0%
Total	28	9	2	6	26	29	100.0%
%	28.0%	9.0%	2.0%	6.0%	26.0%	29.0%	

Table 3: Plaque Characteristics

Side	Carotid bulb	Carotid bulb extending to ECA	Carotid bulb extending to ICA	CCA	CCA Extendig to carotid bulb	Distal CCA	Distal CCA Extendig to ICA	ICA	Mid CCA	Mid CCA extending to ICA	Proximal ICA	%
Left	18	1	5	2	1	1	2	2	1	1	3	52.2
Right	13	0	5	1	0	1	3	6	0	0	5	47.9
Total	31	1	10	3	1	2	5	8	1	1	8	100
%	43.7	1.4	14.1	4.2	1.4	2.8	7	11.3	1.4	1.4	11.3	

Table 4: Plaque Location

% Area stenosis (Rt)	No. of Carotid Vessels (n=34)	Rt ICA PSV(cm/s)		Rt ICA EDV(cm/s)		Rt ICA PSV/Rt CCA PSV	
		Mean	SD	Mean	SD	Mean	SD
<50	23	89.87	13.96	33.5128	3.7966	1.0769	0.2497
50-59	6	146.17	46.88	35.1667	5.1929	1.9333	0.4179
60-69	2	216.50	12.02	70	14.1421	2.5	0.2828
70-79	1	285.00	0.00	110	0.00	4.1	0.00
80-89	1	300.00	0.00	105	0.00	4.5	0.00
90-100	1	280.00	0.00	103	0.00	4.1	0.00

Table 5: Duplex Criteria in Relation with Directly Observed Stenosis (Right Side)

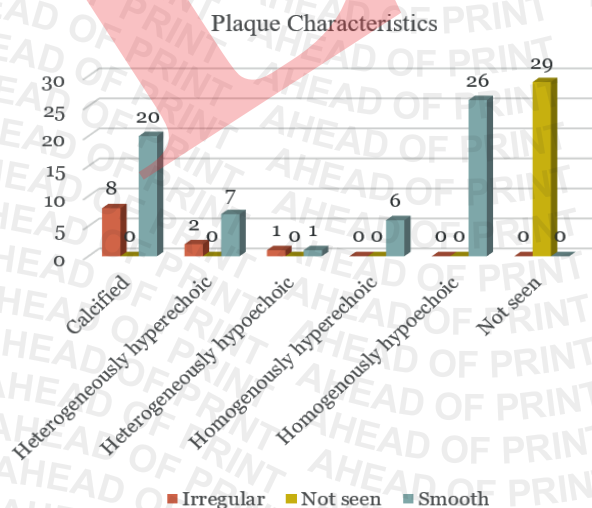


Fig. 2: Plaque Characteristics

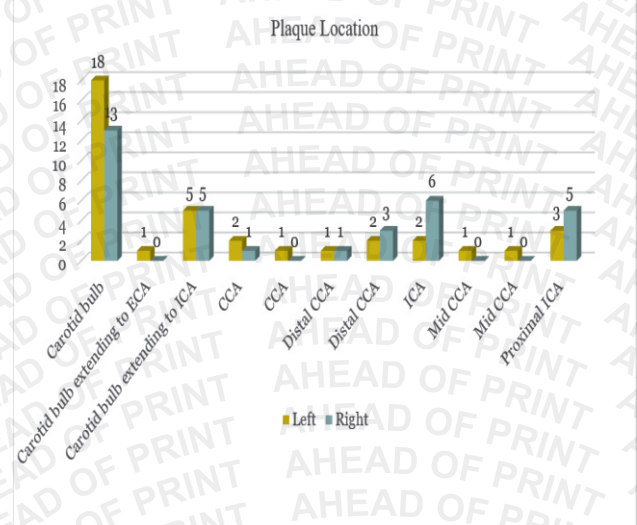


Fig. 3: Plaque Location

% Area stenosis (Lt)	No. of Carotid Vessels (n=71)	Lt ICAPSV(cm/s)		Lt ICAEDV(cm/s)		Lt ICA PSV/Lt CCA PSV	
		Mean	SD	Mean	SD	Mean	SD
<50	52	88.48	9.89	33.17	3.06	1.07	0.22
50-59	9	138.67	52.55	40.33	4.16	1.57	0.72
60-69	4	212.50	10.61	58.00	31.11	2.70	0.42
70-79	3	159.00	86.27	33.50	4.95	1.52	1.39
80-89	2	285.00	0.00	110.00	0.00	4.10	0.00

Table 6: Duplex Criteria in Relation with Directly Observed Stenosis (Left Side)

IMT	Gender	No. of Cases	Mean	SD	P value
Left CCA IMT (mm)	F	14	0.81	0.13	0.0315
	M	36	0.94	0.30	
Right CCA IMT (mm)	F	14	0.76	0.13	0.0109
	M	36	0.98	0.44	

Table 7: Mean IMT Relation with Gender

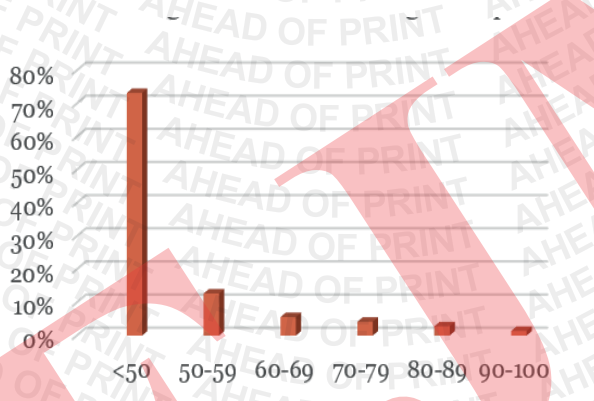


Fig. 4: Percentage area Stenosis.

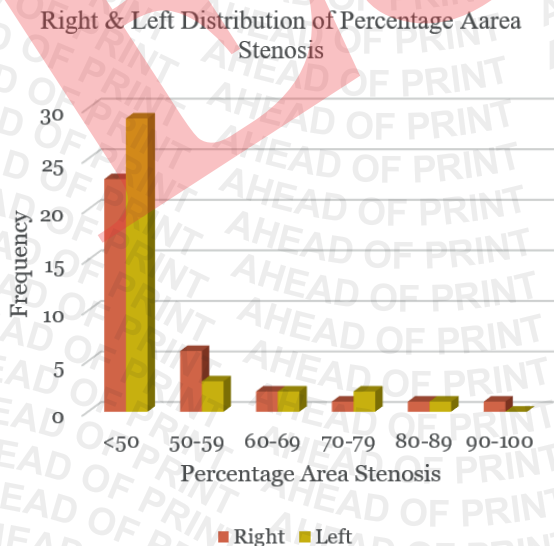


Fig. 5: Distribution of Percentage Area Stenosis in Various Age Groups

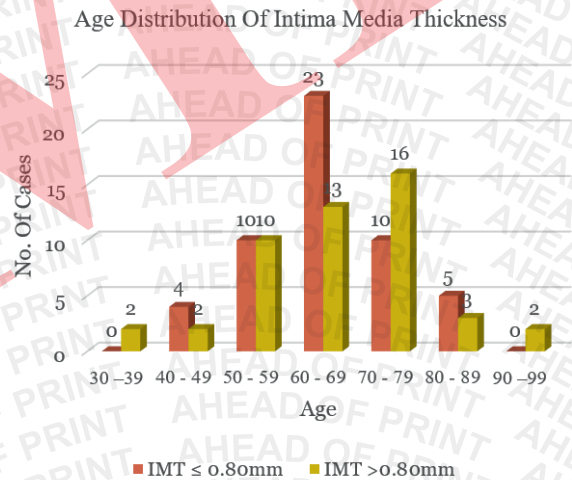


Fig. 6: Age Distribution of Intima Media Thickness

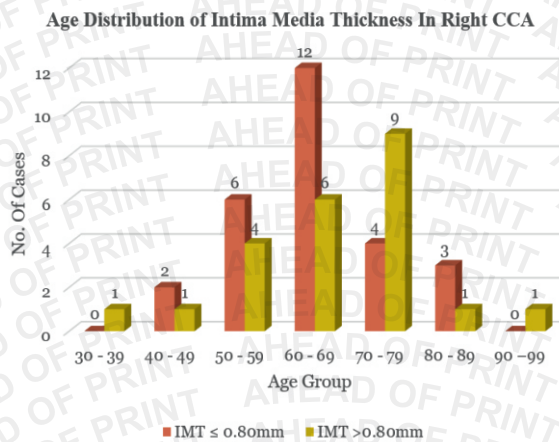


Fig. 7: Age Distribution of Intima Media Thickness in Right CCA

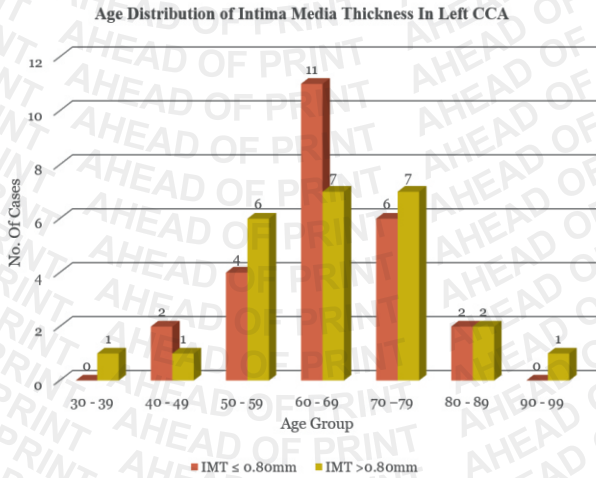


Fig. 8: Age Distribution of Intima Media Thickness in Left CCA

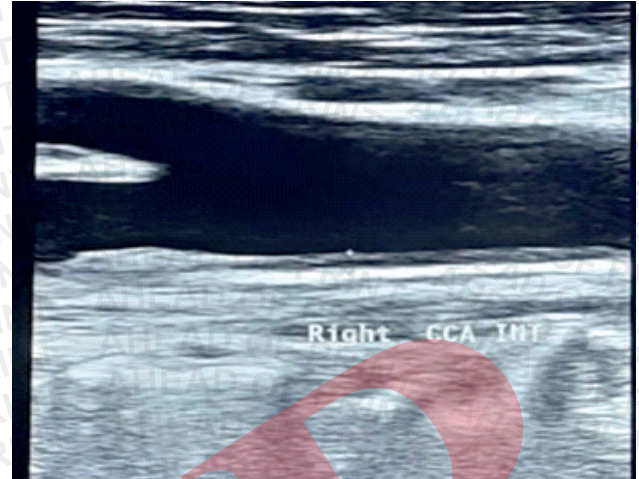


Fig. 11: Gray scale longitudinal image - thickened IMT in right CCA

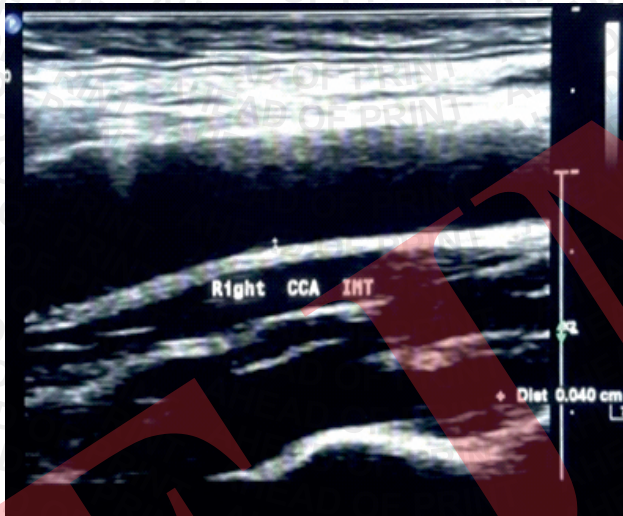


Fig. 9: Gray Scale Longitudinal image Showing normal IMT of right CCA

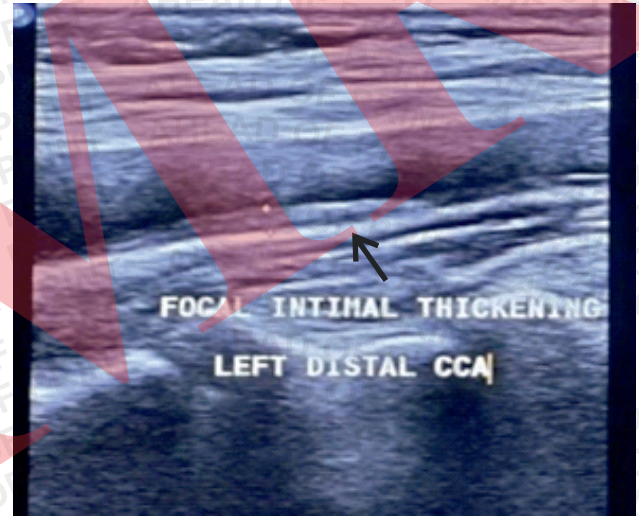


Fig. 12: Gray scale longitudinal image showing focal intimal thickening in left distal CCA

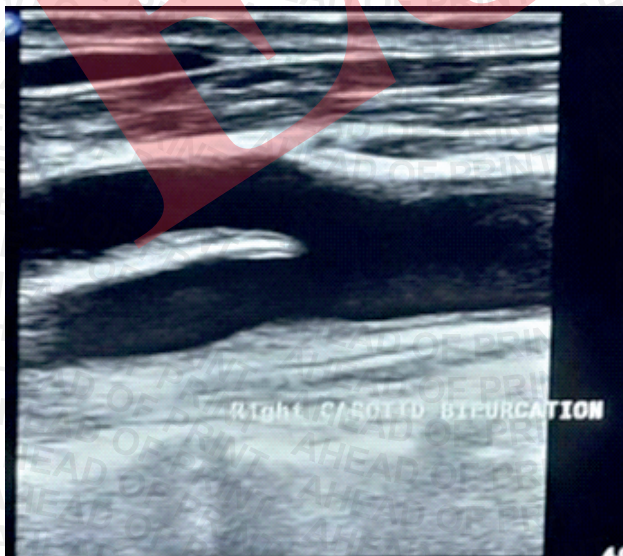


Fig. 10 : Gray Scale Longitudinal Image - Normal Bifurcation of Right Carotid Artery

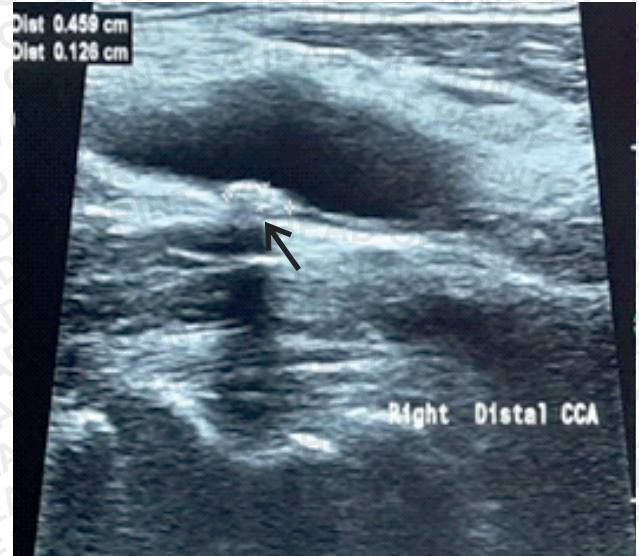


Fig. 13: Gray longitudinal image - hypoechoic plaque with irregular margin in right distal CCA

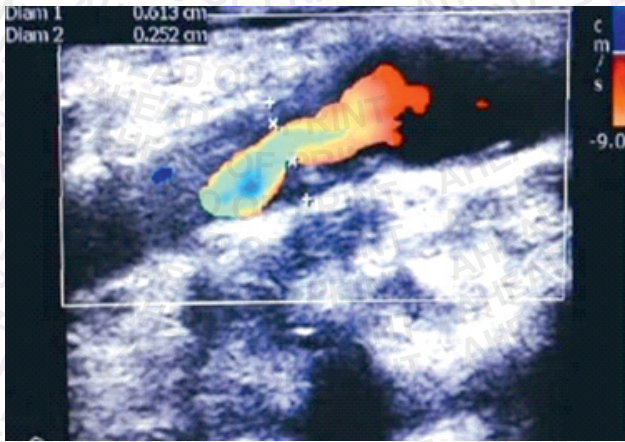


Fig. 14: Colour Doppler images showing reduced colour flow with heterogeneously hyperechoic plaque in Left ICA causing 58.9 % area stenosis

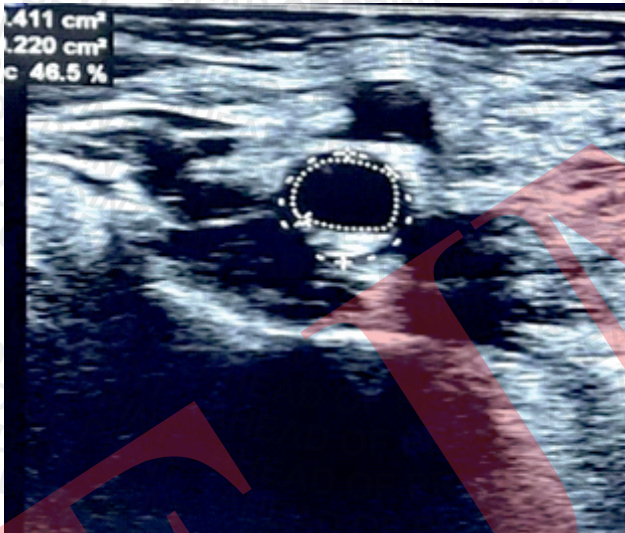


Fig. 15: Gray scale axial image - hyperechoic plaque with smooth margin causing 46.5% stenosis in left CCA

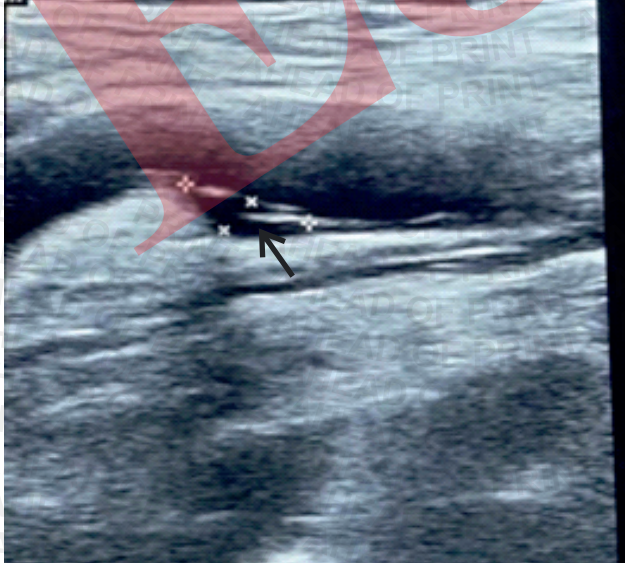

Figure 16: Gray scale longitudinal image showing heterogeneously hypoechoic plaque in left distal CCA

DISCUSSION

The results of this investigation align with previous research highlighting the regularity of carotid artery stenosis in stroke victims. (10). Higher incidence of stenosis in male patients aligns with previous studies that suggest gender as one of the atherosclerotic disease risk factors (11).

This study aimed to evaluate the role of Duplex Ultrasonography in detecting changes in the carotid artery system in 50 patients with suspected cerebrovascular accidents at the Integral Institute of Medical Sciences and Research.

GENDER DISTRIBUTION

Out of 50 patients, 36 (72%) were male, and 14 (28%) were female, consistent with findings from Fernandes et al. and Iemolo et al., showing a similar gender distribution.

AGE DISTRIBUTION

The majority of patients (36%) were in the 60-69 years age group, followed by 26% in the 70-79 age group. The average age of patients was 65.38 ± 11.76 years, comparable to Khatib et al.'s reported mean age of 63.95 ± 10.3 years.

GENDER-WISE AGE DISTRIBUTION

Males predominated in most age groups except for the 50-59 years group, where the gender distribution was equal. In the 60-69 years age group, 13 males and 5 females were represented. Plaque incidence was higher in males, particularly in the 60-70 age group.

PLAQUE CHARACTERISTICS

Plaques were detected in 71 out of 100 arteries, with 39.43% being hypoechoic, 21.13% hyperechoic, and 39.43% calcified. Most plaques (84.5%) had a smooth surface, while 15.49% were irregular. No ulcerations were observed. Calcified plaques were the most common type with irregular surfaces.

PLAQUE LOCATION

Plaques were most commonly located in the carotid bulb (43.7%) and extended into the internal carotid artery (ICA) in 14.1% of cases. Plaques were also found in the common carotid artery (CCA) and external carotid artery (ECA).

STENOSIS DISTRIBUTION

Of the 71 arteries with stenosis, 52 (73.2%) had less than 50% stenosis, with the highest occurrence in the 60-69 age group. Gender differences showed 69.8% of males and 83.3% of females with less than 50% stenosis.

DUPLEX ULTRASONOGRAPHY AND STENOSIS

A correlation between percentage stenosis and increases in peak systolic velocity (PSV) and end-diastolic velocity (EDV) was observed. As stenosis increased, PSV and ICA PSV/CCAPSV ratio also rose.

INTIMA-MEDIA THICKNESS (IMT)

IMT values were higher in patients over 60 years of age, with 48% of arteries exceeding the normal threshold of 0.80mm. Age-wise, a significant increase in IMT was observed with advancing age, consistent with findings from Saxena et al.

IMT AND GENDER

No significant differences in IMT were found between genders in either the left or right CCA. However, males generally had higher IMT values compared to females, a trend observed in similar studies by Mazurek et al. Color Doppler sonography is an effective non-invasive tool for assessing carotid arteries, allowing detailed visualization of plaque morphology and blood flow, aiding in stroke risk evaluation. This study advocates for its routine use in stroke diagnostics, particularly in high-risk patients. However, limitations include its cross-sectional design and small sample size, affecting generalizability. Future research should focus on larger, longitudinal studies to validate these findings and explore the role of carotid sonography in stroke prevention.

CONCLUSION

This study demonstrates high rate of carotid artery stenosis prevalence among stroke individuals and underscores the importance of routine carotid evaluation using colour Doppler sonography. Early detection of carotid artery stenosis can lead to timely interventions, potentially reducing the risk of recurrent strokes. Colour Doppler sonography should be considered an integral part of stroke management protocols in tertiary care settings.

REFERENCES

1. Carrol B A. Carotid sonography. Radiology 1991; 178: 303-313.

Orcid ID:

Kanika Malhotra - <https://orcid.org/0009-0007-8874-8126>
Lavan Saxena - <https://orcid.org/0009-0000-3087-150X>
Ganesh Kumar - <https://orcid.org/0009-0006-2240-5203>
Abhishek Agrawal - <https://orcid.org/0009-0008-0891-0523>
Zeeshan Siddiqui - <https://orcid.org/0009-0004-9747-0291>

How to cite this article:

Malhotra K, Saxena L, Kumar G, Agrawal A, Siddiqui Z. Evaluation of Carotid Arterial System in Stroke Patients Using Colour Doppler Sonography in a Tertiary Care Institute. Era J. Med. Res. 2024; 11(2): X-X.

Licencing Information

Attribution-ShareAlike 2.0 Generic (CC BY-SA 2.0) Derived from the licencing format of creative commons & creative commons may be contacted at <https://creativecommons.org/> for further details.

2. Grant E G, Benson C B, Moneta G L, et al. Carotid artery stenosis: grayscale and Doppler ultrasound diagnosis-Society of Radiologists in Ultrasound consensus conference. Ultrasound Q. 2003 Dec;19(4):190-198.
3. Kelley R E. Noninvasive cardiovascular studies. Neurology in clinical practice (principles of diagnosis and management), 2nd ed., Chapter 38, p.499.
4. Wade S. smith, S. Claiborne Johnston, J. Donald Easton; Carotid atherosclerosis, cerebro vascular diseases Harrison's Principles of Internal Medicine 16th edition chapter 349, page2377
5. Colin Deane. Doppler Ultrasound-Principles and Practice. Available at [URL], accessed on May 8, 2021.
6. Dreisbach J N, Seibert C E, Smazal S F, et al. Duplex sonography in the evaluation of carotid artery disease. American Journal of Neuroradiology. 1983 May 1; 4(3):678-80.
7. Nezu T, Hosomi N. Usefulness of Carotid Ultrasonography for Risk Stratification of Cerebral and Cardiovascular Disease. J Atheroscler Thromb. 2020 Oct 1;27(10):1023-1035.
8. Bornstein N M, Beloev Z G, Norris J W. The limitations of diagnosis of carotid occlusion by Doppler ultrasound. Annals of surgery. 1988 Mar; 207(3): 315.
9. Polak J F, O'Leary D H, Kronmal R A, et al. Sonographic evaluation of carotid artery atherosclerosis in the elderly: relationship of disease severity to stroke and transient ischemic attack. Radiology. 1993 Aug;188(2):363-70.
10. Derdeyn C P, Powers W J, Moran C J, Cross 3rd D T, Allen B T. Role of Doppler US in screening for carotid atherosclerotic disease. Radiology. 1995 Dec;197(3):635-43.
11. Razzaq A A, Khan B A, Jadoon C K, Baig S M. Carotid Doppler ultrasonography in young stroke patients. Journal of Pakistan Medical Association. 1999;49(4):97.

