

SURGICAL APPROACH TO A LARGE DENTIGEROUS CYST AND ASSOCIATED IMPACTED TEETH:INSIGHTS FROM A CLINICAL CASE

Vidya M S , Sachin Aslam A, Mathew PC, Tom Thomas, Anu Jose

Department of Oral and Maxillofacial Surgery

MES Dental College and Hospital, Perinthalmanna, Kerala, India - 679321

Received on : xx-xx-xxxx

Accepted on : xx-xx-xxxx

Address for correspondence

Dr. Vidya MS

Department of Oral and Maxillofacial
Surgery

MES Dental College and Hospital,

Perinthalmanna, India - 679321

Email: vidyams265@gmail.com

Contact no: +91-9074531255

ABSTRACT

Cysts in the oral and maxillofacial regions are common, accounting for about 20% of all lesions in oral and maxillofacial pathology. Diagnosing cysts within the jaw bones are particularly accounts for second most cyst of jaw typically occur in the age group 2- to 30 years and a definitive diagnosis usually requires histological examination of the cyst, along with clinical and radiological assessments. Here a case report of thirteen-year-old girl with painless enlargement over her lower front teeth, diagnosed with a dentigerous cyst, who successfully underwent enucleation was explained.

KEYWORDS: Dentigerous Cyst, REE (reduced Enamel Epithelium), Impacted Teeth, Enucleation, Aspiration.

INTRODUCTION

Dentigerous cyst is lined by epithelium that encircles the crown of an impacted or unerupted tooth (1). Dentigerous cyst accounts for about 25% of all tooth related cystic lesions. It is a benign, slow growing and developmental in origin. These develops when fluid accumulates in the middle of REE and unerupted tooth's crown. Normally, the follicular space measures three-four mm; if this space is greater than five mm, a dentigerous cyst is suspected (2). Dentigerous cysts generally do not cause pain or discomfort unless they become secondarily infected, and are often found incidentally on radiographs. On radiographs, these cysts appear as unilocular well defined radiolucent areas with sclerotic margins, typically around an unerupted/impacted tooth (3). Dentigerous cysts occurs as either solitary or numerous in cases with Gardner's syndrome, basal cell nevus syndrome and Cleidocranial dysplasia (3).

CASE REPORT

A thirteen years old female patient presented to Oromaxillofacial department with the complaint of pain and swelling over lower front teeth region since few months. She noticed gradual increase in size of the chin. On extraoral examination mild facial asymmetry on right side was noted (Fig 1). Mouth opening was adequate.

On intraoral examination, a diffuse swelling of size 6 cm x 3 cm extending from 33 to 46 with labial and

vestibular obliteration was noted & hard on palpation which was covered by normal oral mucosa (Fig 2). She was not syndromic and in good health condition.

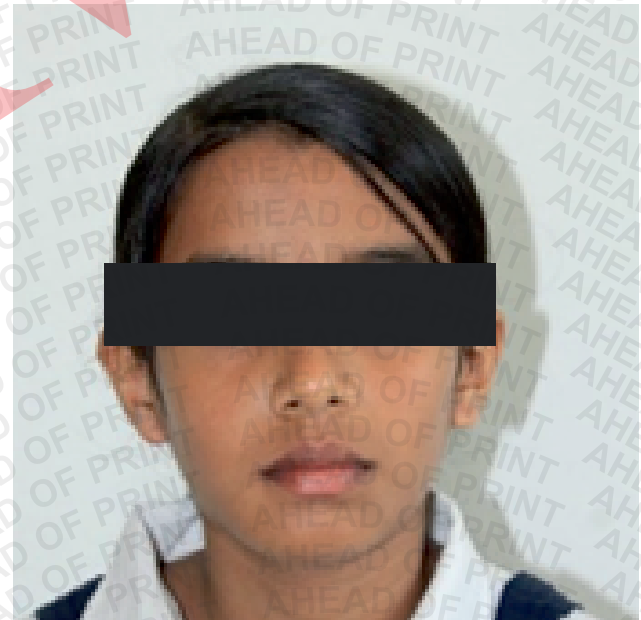

FIG. 1: Extraoral Photograph

IMAGING

The orthopantomogram shows a well-defined radiolucency with radiopaque border extending from 33 to 46 region with multiple impacted teeth irt 43,44 and 45 (Fig 3).

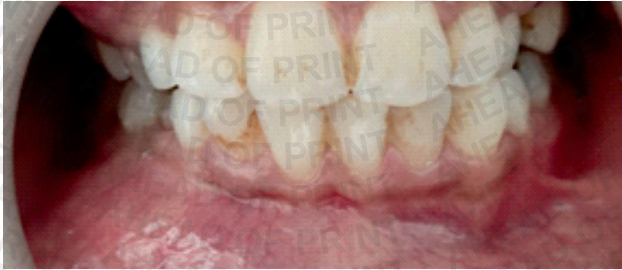

Fig. 2: Intraoral Swelling Extending from 33 to 46 Region

MANAGEMENT

Incisional biopsy was done under local anaesthesia showed a straw coloured fluid on aspiration & collected specimen sent for histopathological examination (Fig 5). A differential diagnosis of dentigerous cyst was made according to above described features.

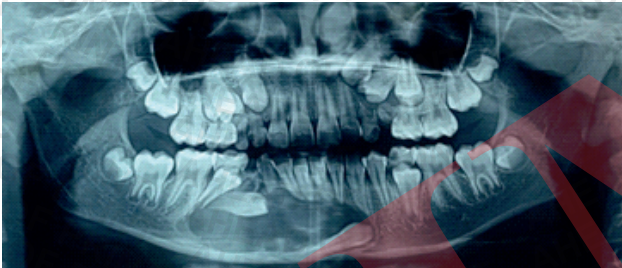

Fig. 3: Orthopantomogram

After obtaining fitness for the planned procedure the patient was aseptically prepared for cyst enucleation and surgical removal of impacted teeth under general anaesthesia. Crevicular incision made from 35 to 46 region with releasing incisions bilaterally. Full thickness mucoperiosteal flap raised buccally. There was a change in bony architecture when compared to normal bone. Bone guttering done buccally and lesion exposed. Complete lesion along with impacted 43,44,45 enucleated in toto. Irregular bony surfaces contoured using round bur. Haemostasis achieved by using cautery(FIGURE 6). After copious irrigation using Gentamicin & metronidazole, surgical cavity packed with haemostatic agent, closure was done using Vicryl (I). On recall, healing was satisfactory and uneventful.

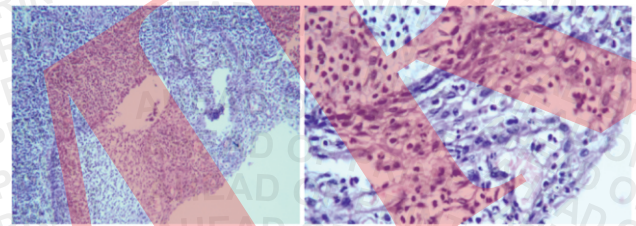


Fig. 7: Histopathological Findings

Histopathological report showed stratified squamous epithelium which is non keratinised,thick with 2-3 layers and the inflammatory cell infiltrate connective

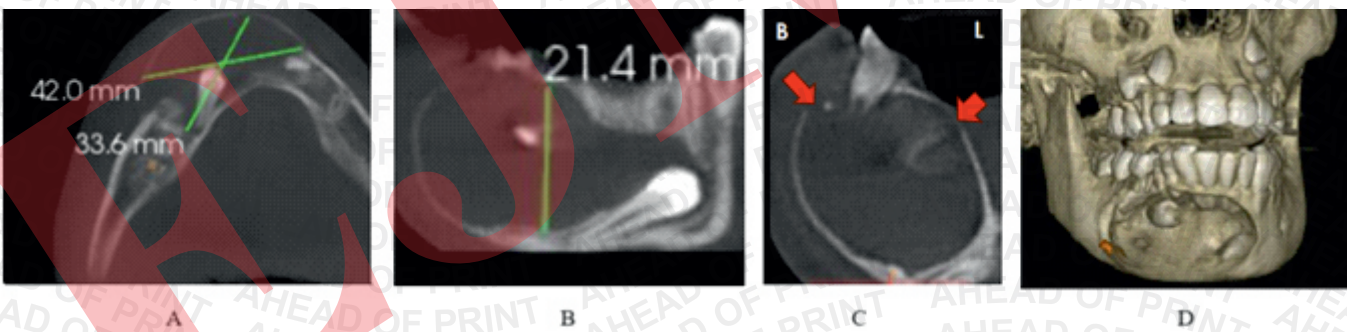
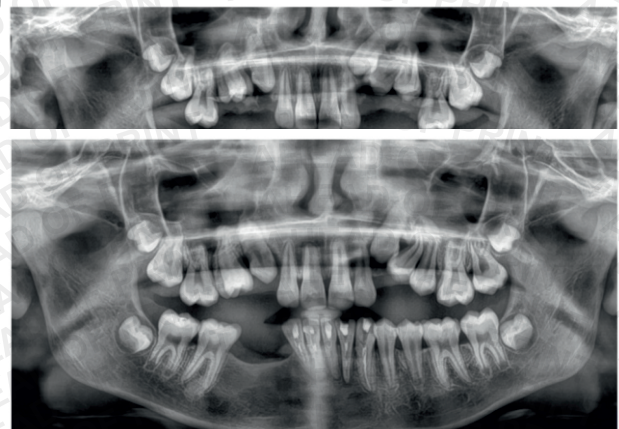


FIGURE 4 - (A) CBCT axial section showing hypodense lesion of size 42mm x 33.6mm extending from 33 to 46 region. (B)CBCT coronal section showing hypodense lesion of 21.4 mm size superoinferiorly extending from alveolar crest upto lower border of the mandible. (C) Expansion, thinning and breach of buccal/labial and lingual cortical plates. (D) 3D model of the jaw.

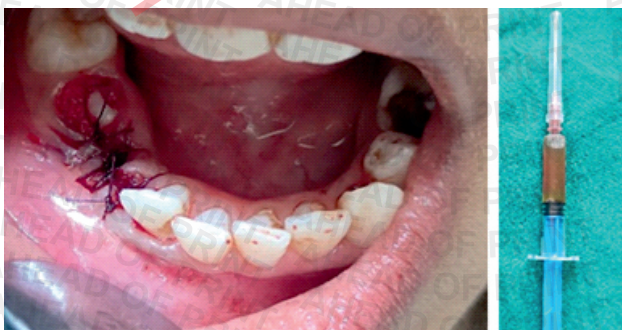

Fig. 5: Incisional biopsy, Aspiration revealed straw coloured fluid



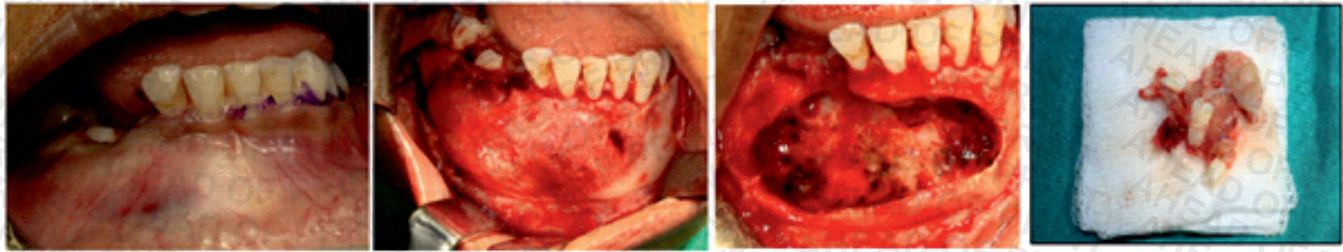


FIGURE 6 - Intraoperative photographs (A) Crevicular incision placed (B) Full thickness mucoperiosteal flap raised and lesion exposed (C) Surgical cavity after enucleation of the lesion (D) Specimen showing enucleated cyst with impacted 43,44,45

occasionally from odontomas. Dentigerous cysts are often found incidentally during radiographs, appearing as small radiolucent lesions. However, if not treated early, these cysts can grow significantly, potentially disrupting surrounding teeth, causing root resorption, or even invading and altering the surrounding bone (7,8).

Those patients with dentigerous cyst who are in the mixed dentition, caries from deciduous tooth may spread periapically and cause inflammation of the underlying developing tooth buds resulting in formation of cyst. In that cases patients are presented with both pain and swelling, then that cyst will be of inflammatory in etiology and are mostly associated with the developing lower premolar (9).

Histopathology of dentigerous cyst showed that the wall of cyst is thin and is lined by stratified squamous epithelium which is non keratinised and is of 2-3 layers thickness. Abundant cholesterol clefts are present in the cystic fluid which is in accordance to the histopathology report of our case.

The treatment methods for dentigerous cysts are marsupialization (Partsch I), enucleation (Partsch II) and Waldron's method. The choice of method based on : the size and site of the cyst, whether to remove or preserve the unerupted tooth, the age of the patient , comorbidities and the feasibility of follow-up. Marsupialization is a conservative method involves suturing the walls of the cystic cavity to the adjacent mucosa after decompression. It is preferred when preserving displaced teeth is desirable, especially in young patients (9,10).

In the current case the position of impacted teeth was unfavourable for marsupialisation and the presence of an intact lingual wall and thick lower border of mandible enabled us to perform deroofing and complete enucleation followed by packing with gelatin sponge for packing the cavity. Intraoperative topical steroid over lips with steroid cream (Betamethasone) and postoperative icepack compression yielded minimal post operative oedema and pain. Paresthesia was not present over right side of lips and chin & patient was discharged on third

postoperative day.

CONCLUSION

Dentigerous cyst commonly associated with an unerupted tooth & sometimes it is an accidental finding in the radiographs. Orthopantomogram is always an initial basic radiographic investigation for ruling out of the same. Proper planning according to the patient history, clinical, radiological ,histological findings is mandatory. Larger cystic lesions liked the ones described in this case report requires management under general anesthesia and prior planning to optimize post surgical outcomes and to reduce complication rates.

REFERENCES

1. Kaushik A, et al. Non-syndromic bilateral dentigerous cysts of maxillary and mandibular canines: A case series and review of literature. J Oral Maxillofac Surg Med Pathol (2015)
2. Avinash T, Sandhya T, Daivat B, Sudhir B, Treville P, Mukul P. Bilateral dentigerous cyst in a non-syndromic patient: report of an unusual case with review of the literature. J Oral Maxillofac Pathol 2011;15:91-5.
3. Shawneen MG, Peter MS, Jeffrey BP, Peter JG. A dentigerous cyst associated with bilaterally impacted mandibular canines in a girl: a case report. J Med Case Rep 2011;5:230
4. Sivapathasundharam B. Shafer's Textbook of Oral Pathology. India: Elsevier Health Sciences 2020 Jul 15
5. Shear M, Speight P. Cysts of the oral and maxillofacial regions. 4th edn. Munksgaard, Oxford: Blackwell 2007:69- 70
6. Dhupar A, Yadav S, Dhupar V, Mittal HC, Malik S, Rana P. Bi-maxillary dentigerous cyst in a non-syndromic child—review of literature with a case presentation. Journal of Stomatology, Oral and Maxillofacial Surgery. 2017 Feb 1;118(1):45-8.
7. Tournas AS, Tewfik MA, Chauvin PJ, Manoukian JJ. Multiple unilateral maxillary dentigerous cysts in a non-syndromic patient: a case report

and review of the literature. International Journal of Pediatric Otorhinolaryngology Extra. 2006 Jun 1;1(2):100-6.

8. Kaushik A, Chaudhry A, Saluja P, Kumar M, Varshney M. Non-syndromic bilateral dentigerous cysts of maxillary and mandibular canines: A case series and review of literature. Journal of Oral and Maxillofacial Surgery, Medicine, and Pathology. 2015 Jul 1;27(4):562-6.

9. Joshi M, Samuel S, Abraham A, et al. Management of Dentigerous Cysts-A Review. Journal of Evolution of Medical and Dental Sciences. 2021 Jun 28;10(26):1948-54.

10. Chybicki D, Popielarczyk A, Markowski W, Torbicka G, Janas-Naze A. Infected dentigerous cyst of maxillary sinus mimicking intraoral abscess in a pediatric patient: Management of misdiagnosis and inaccurate treatment. Case Reports in Dentistry. 2022;2022(1):4852464.



ERA'S JOURNAL

Orcid ID:

Vidya MS - <https://orcid.org/0009-0003-9963-8118>

Sachin Aslam A - <https://orcid.org/0009-0000-7197-6458>

Mathew PC - <https://orcid.org/0000-0002-0689-8048>

Tom Thomas - <https://orcid.org/0000-0001-8349-7582>

Anu Jose - <https://orcid.org/0000-0001-5122-6534>

How to cite this article:

MS Vidya, A Aslam Sachin, PC Mathew, Thomas T, Jose A. Surgical Approach to A Large Dentigerous Cyst And Associated Impacted Teeth: Insights From A Clinical Case. Era J. Med. Res. 2024; 11(2): X-X.

Licencing Information

Attribution-ShareAlike 2.0 Generic (CC BY-SA 2.0) Derived from the licencing format of creative commons & creative commons may be contacted at <https://creativecommons.org/> for further details.