

ASSESSMENT OF NON-INVASIVE TESTS IN HBeAg-NEGATIVE CHRONIC HEPATITIS B

Meral Sozen

Department of Gastroenterology

Dr. Meral Sözen Clinic, Ufuk Üniversitesi Straat, The Paragon Tower Çukurambar No:17-3 Çankaya, Türkiye-06530

Received on : 25-11-2024

Accepted on : 31-12-2024

ABSTRACT

Overview: In this study, individuals with Recurrent hepatitis B with HBeAg-negative have their liver fibrosis and inflammation assessed using non-invasive diagnostic assays for accuracy and clinical value. In order to ascertain how well these techniques differentiate between HBeAg-negative CHB and dormant carriers of the hepatitis B surface antigen it contrasts them with conventional liver biopsies. The study also investigates how these tests might be used to track the effectiveness of antiviral therapy. Blood-based indices were evaluated, including the APRI ratio, the fibrosis-iv index, the neutrophil-to-lymphocyte (N/L) ratio, and the alanine aminotransferase-to-aspartate aminotransferase (AAR) ratio. Results highlight the potential of non-invasive methods as reliable alternatives to liver biopsy, paving the way for improved management of CHB. Two participant groups were established according to the METAVIR grading scheme. Each participant underwent measurements of several clinical indices, including the fibrosis-4 index, the (N/L) ratio, the alanine aminotransferase to AAR ratio, and APRI ratio." The mean platelet volume (MPV), AAR, FIB-4, APRI, N/L ratio, and platelet count had AUROC values of 0.581, 0.558, 0.502, 0.505, 0.506, and 0.460, respectively. To determine if fibrosis was substantial or progressed, platelet counts were employed (METAVIR ≥ 2). APRI, FIB-4, N/L ratio, MPV, AAR, for detecting severe fibrosis (METAVIR = 2), and platelet count exhibited corresponding AUROCs of 0.473, 0.451, 0.484, 0.503, 0.525, and 0.605. Clinical evaluations for each participant included determining several indices: the fibrosis-4 (FIB-4) index, the ratio of (N/L), the ratio of APRI to AAR, and the ratio of aspartate aminotransferase to platelets (APRI)." According to our research, severe fibrosis has only been partially detected via non-invasive diagnostic methods like APRI and FIB-4. Due to its unreliability, liver biopsies cannot currently be used in place of these assays. They are only applicable to Individuals who do not make excellent liver biopsies

KEYWORDS: Non-invasive test, HBeAg-negative CHB, APRI, FIB-4, liver biopsy.

INTRODUCTIONA major global health issue, chronic hepatitis B affects about two hundred fourty million people who have been long-term carriers of the hepatitis B virus. Liver cirrhosis and fibrosis are serious adverse effects of this illness that may lead to cancer or liver failure. CHB is classified into two subtypes, one of which contains the HBeAg and the other does not (1,2). There are over two hundred ninety six million people infected with chronic hepatitis B globally, making it a major health burden. Chronic liver fibrosis and inflammation are hallmarks of HBeAg-negative CHB, which calls for antiviral treatment. while inactive carriers typically have minimal liver damage and do not require immediate treatment (3, 4). Depending based the degree of liver damage and the quantity of viral replication, this

subtype can be further classified into two groups. People who do not have severe liver necroinflammation and are inactive HBsAg carriers fall into the first group. Individuals with substantial fibrosis and HBeAg-negative, moderate liver inflammation, and normal or raised Alanine Aminotransferase (ALT) values are included in the second group (5,6). Patients with active HBeAg-negative CHB require therapy to avoid the development of cirrhosis and its related consequences, whereas those with the inactive hepatitis B carrier status do not require treatment. Therefore, it is essential to differentiate between these two types of the illness in order to choose the best management and treatment plan (4, 5). Preventing chB issues requires early detection and treatment. The standard for staging

Address for correspondence

Dr. Meral Sozen

Department of Gastroenterology
Dr. Meral Sözen Clinic, Ufuk Üniversitesi
Straat, The Paragon Tower Çukurambar
No:17-3 Çankaya, Türkiye
Email: gurjeetsingh360@gmail.com
Contact no: +90-5355889597

liver fibrosis is acknowledged to be the liver biopsy. The potential for sample errors, the potential for different observers to interpret the histology, and the associated risks of complications and mortality are only a few of the drawbacks of this invasive procedure. Scientists are presently searching for non-invasive, reliable, and different methods for tracking the development of liver disease due to these constraints. However, none of these serum-based diagnostics are accurate enough. There is also ongoing debate over how well these non-invasive tests reflect developments in antiviral drugs. Currently, there is a dearth of comprehensive research on this topic, and the findings of various studies range greatly.

MATERIAL AND METHODS

The outcomes served as the benchmark for assessing the accuracy of non-invasive testing. ROC curves, which especially target patients with co-infections like HIV and hepatitis C, were used to calculate the area under the curve (AUC) for each test. The AUC results offer a solid assessment of the efficacy of non-invasive techniques for predicting fibrosis in these individuals, amply demonstrating the tests' sensitivity and specificity, liver transplant recipients, autoimmune liver illnesses, liver cancer, metabolic liver disorders, and those who drank more than 20 grams of alcohol daily were excluded. Several participant characteristics, such as mean platelet volume (MPV), age, gender, aspartate aminotransferase (AST), neutrophil and lymphocyte counts HBV DNA levels and alanine aminotransferase (ALT) were measured. The FIB-4 index, APRI index, ALT/AST ratio (AAR), and NL ratio were all computed using established formulas. A 17-gauge needle was used to take liver samples under ultrasound guidance. After that, the samples were embedded in paraffin and kept in formalin. We set a criterion that required at least 15 mm of liver tissue that included at least six portal tracts in order to ensure the accuracy of our histological investigation. Using the METAVIR scoring system, we methodically assessed the liver's fibrosis and inflammation levels. We were able to distinguish between individuals with Significant/Advanced fibrosis (METAVIR scores of 2-4) and those with No/Mild fibrosis (METAVIR scores of 0-1) because to this thorough methodology.

For statistical analysis, IBM SPSS Statistics version 22.0, was used. Standard deviation (SD) \pm mean was used to summarize the data. Categorical data were assessed using the Chi-Square test, while continuous variables were examined using the Student's t-test or paired samples t-test. By predicting fibrosis using the

area under the receiver operating characteristic curve (AUROC), the diagnostic performance of non-invasive techniques was evaluated. P-values below 0.05 were considered statistically significant. The study complied with ethical guidelines and obtained the required authorization from the appropriate authorities.

RESULTS

159 people participated in the study, 85 of those were men (53.5%), and 74 of were women (46.5%). Each participant's biochemical, histological, and demographic information is shown in Table 1. The groups with advanced or substantial fibrosis and those with little or moderate fibrosis did not vary statistically significantly ($p > 0.05$) in terms of age, gender, or other biochemical and hematological characteristics.

On the other hand, across the two groups, the p-values for AAR, MPV, platelet counts, and NL ratio were comparable, coming in at 0.237, 0.754, 0.360, and 0.622, respectively (Table 2). ROC curve analysis revealed that 0.226 was the ideal APRI cut-off value for identifying significant/advanced fibrosis. This resulted in 62.3% sensitivity, 49.1% specificity, 37.9% PPV, and 72.2% NPV (AUROC: 0.581), as shown in Table 3, Figure 1A. At a threshold value of 0.240, the AUROC for APRI in identifying severe fibrosis (METAVIR = 2) was determined to be 0.473 (Table 4, Figure 1B).

According to Table 3, Figure 1A, the FIB-4 index likewise had a 0.558 AUROC and a threshold value of 1.012, which translated into a PPV of 38.8% and an NPV of 71.1% indicated substantial/advanced fibrosis, along with a 50.0% sensitivity and a specificity of 61.0%. FIB-4's AUROC was 0.451, with a cut-off value of 0.822 for predicting significant fibrosis (METAVIR = 2) (Table 4, Figure 1B).

With matching AUROC values of 0.502, 0.505, 0.506, and 0.460, the N/L ratio, MPV, AAR, and platelet count were predictive of substantial or advanced fibrosis (Table 3, Figure 1A). These indicators had AUROC scores of 0.484, 0.503, 0.525, and 0.605 to detect substantial fibrosis (METAVIR = 2) (Table 4, Figure 1B). The distribution of FIB-4 and APRI levels across fibrosis phases is shown in Figure 2A-B.

Lamivudine was administered to two patients, tenofovir disoproxil fumarate to two, and entecavir to 80 APRI and FIB-4 scores decreased following therapy as compared to their pre-treatment values, although these decreases ($p = 0.210$ and $p = 0.516$, respectively) fell short of statistical significance. MPV, AAR, N/L ratio, and platelet count did not

change significantly before or after therapy; their respective p-values were 0.094, 0.423, 0.431, and 0.134. HBV DNA concentrations did not change. however, dramatically dropped following treatment (p = 0.016) (Table 5).

DISCUSSION

The findings underscore the clinical value of non-invasive tests in managing HBeAg-negative CHB. Among the indices evaluated, the FIB-4 index and APRI emerged as the most reliable markers for liver fibrosis. The N/L ratio showed promise as an inflammation marker but requires further validation. These diagnostic instruments provide a more cost-effective and secure substitute for liver biopsies and aid in the early diagnosis and tracking of treatment results. APRI and FIB-4 worked together to provide exceptional diagnostic accuracy, suggesting a

synergistic effect. This approach could significantly reduce reliance on invasive procedures, particularly in resource-limited settings. However, integrating non-invasive tests into routine clinical practice requires standardization of cut-off values and further multicentric validation studies. Before starting successful antiviral medication, it is critical to differentiate between individuals with inactive HBsAg carriers and those with HBeAg-negative CHB. While liver biopsy remains the gold standard for accurately diagnosing hepatic fibrosis, its invasive nature carries inherent risks, including complications and even mortality. Therefore, the development of non-invasive methods for assessing liver disease has become imperative for safer diagnosis and patient care, including imaging techniques and mathematical models that use both direct and indirect blood indicators. APRI and FIB-4 are helpful markers of

| | |
|--|---|
| Age | 46.86±12.13 |
| Gender (Female / male) | 74 (46.5%) / 85 (53.5%) |
| Histological Activity Index A0 / A1 / A2 | 109 (68.6%) / 49(30.8%) / 1 (0.6%) |
| Fibrosis F0 / F1 / F2 / F3 / F4 | 29 (18.2%) / 77(48.4%) / 28 (17.6%) / 15(9.4%) / 10(6.3%) |
| HBVDNA (copies/mL) | 7941442.06±71236351.39 |
| Alanine aminotransferase (IU/L) | 44.12±137.40 |
| Aspartate aminotransferase (IU/L) | 28.37±27.80 |
| Platelets (10 ⁹ /L) | 2135.09±58.99 |
| Mean platelet volume (fL) | 9.25±1.32 |
| Lymphocyte (10 ⁹ /L) | 4.14±1.40 |
| Neutrophil (10 ⁹ /L) | 2.40±1.33 |

Table 1: Baseline characteristics of the study group

| | No/Mild Fibrosis (No:106) | Significant/Advance Fibrosis (No: 53) | P |
|-------------------------------------|--------------------------------------|--|----------|
| Age | 47.04±12.15 | 46.50±12.21 | 0.793 |
| Gender Female/Male | 50 (47.2%) / 56 (52.8%) | 24 (45.3%) / 29 (54.7%) | 0.822 |
| AST (IU/L) | 24.90±17.67 | 35.30±40.54 | 0.079 |
| ALT (IU/L) | 46.78±166.40 | 38.81±37.49 | 0.731 |
| MPV (fL) | 9.23±1.30 | 9.30±1.36 | 0.754 |
| Platelet (10 ⁹ /L) | 235.97±54.83 | 226.87±66.29 | 0.360 |
| Neutrophil/Lymphocyte | 2.01±0.97 | 2.10±1.46 | 0.622 |
| AAR | 0.91±0.32 | 0.99±0.057 | 0.237 |
| APRI | 0.27±0.19 | 0.50±0.81 | 0.007 |
| FIB-4 | 0.95±0.48 | 1.45±2.03 | 0.019 |
| HBV-DNA 10 ⁶ (copies/mL) | 1.47±6.03 | 21.38±124.43 | 0.101 |

ALT: Alanine aminotransferase, AST: Aspartate aminotransferase MPV: Mean platelet volume, AAR: ALT/AST Ratio, APRI: Aspartate aminotransferase to platelet ratio index, FIB-4: Fibrosis-4.

Table 2: Comparison of the demographics, laboratory and non-invasive markers of the patients with No/Mild fibrosis and Significant/Advance fibrosis

| | Cut-off | AUROC | Sensitivity | Specificity | PPV | NPV |
|-----------------------|---------|-------|-------------|-------------|------|------|
| MPV | 9.050 | 0.505 | 60.3 | 48.1 | 37 | 70 |
| Platelet | 219.500 | 0.460 | 54.7 | 38.6 | 30.8 | 63.1 |
| Neutrophil/Lymphocyte | 1.713 | 0.502 | 64.1 | 49.1 | 38.6 | 73.2 |
| AAR | 0.883 | 0.506 | 49.1 | 50.0 | 33.3 | 66.3 |
| APRI | 0.226 | 0.581 | 62.3 | 49.1 | 37.9 | 72.2 |
| FIB-4 | 1.012 | 0.558 | 50.0 | 61.0 | 38.8 | 71.1 |

ALT: Alanine aminotransferase, AST: Aspartate aminotransferase MPV: Mean platelet volume, AAR: ALT/AST Ratio, APRI: Aspartate aminotransferase to platelet ratio index, FIB-4: Fibrosis-4.

Table 3: Performance of non-invasive tests to distinguish No/Mild fibrosis from Significant/Advance fibrosis

| | Cut-off | AUROC | Sensitivity | Specificity | PPV | NPV |
|-----------------------|---------|-------|-------------|-------------|------|------|
| MPV | 9.050 | 0.503 | 64.3 | 48.1 | 24.7 | 83.6 |
| Platelet | 233.500 | 0.605 | 60.7 | 51.9 | 25.0 | 83.3 |
| Neutrophil/Lymphocyte | 1.724 | 0.484 | 57.1 | 49.1 | 22.9 | 81.3 |
| AAR | 0.885 | 0.525 | 50.0 | 57.1 | 20.9 | 79.1 |
| APRI | 0.240 | 0.473 | 48.1 | 52.8 | 20.6 | 80.0 |
| FIB-4 | 0.822 | 0.451 | 50 | 45.7 | 19.7 | 77.4 |

ALT: Alanine aminotransferase, AST: Aspartate aminotransferase MPV: Mean platelet volume, AAR: ALT/AST Ratio, APRI: Aspartate aminotransferase to platelet ratio index, FIB-4: Fibrosis-4.

Table 4: Performance of non-invasive tests to distinguish No/Mild fibrosis from Significant Fibrosis

| | Before Antiviral Therapy | Post Antiviral Therapy | P |
|------------------------------------|--------------------------|------------------------|-------|
| AST (IU/L) | 28.27±27.94 | 17.89±1.43 | 0.430 |
| ALT (IU/L) | 44.29±137.82 | 31.64±31.80 | 0.265 |
| MPV (fL) | 9.30±1.30 | 9.43±1.10 | 0.094 |
| Platelet (10 ⁹ /L) | 232.31±59.81 | 2.35±58.99 | 0.423 |
| Neutrophil/Lymphocyte | 2.02±1.13 | 2.29±2.17 | 0.134 |
| AAR | 0.94±0.42 | 0.98±0.48 | 0.431 |
| APRI | 0.35±0.51 | 0.30±0.23 | 0.210 |
| FIB-4 | 1.12±1.28 | 1.07±0.71 | 0.516 |
| HBVDNA 10 ⁶ (copies/mL) | 2.34±9.71 | 0.22±2.47 | 0.016 |

ALT: Alanine aminotransferase, AST: Aspartate aminotransferase MPV: Mean platelet volume, AAR: ALT/AST Ratio, APRI: Aspartate aminotransferase to platelet ratio index, FIB-4: Fibrosis-4.

Table 5: Comparison of the laboratory and non-invasive markers of the patients before and after treatment

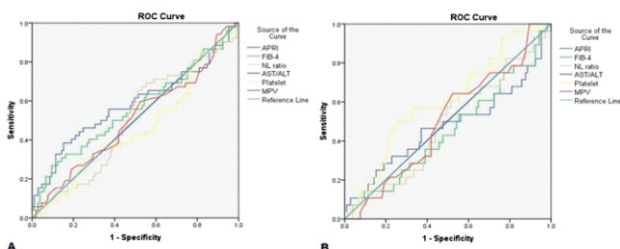


Fig. 1: A- ROC curves of non-invasive test to distinguish No/Mild fibrosis from Significant/Advance fibrosis. B- ROC curves of non-invasive test to distinguish No/Mild fibrosis from Significant fibrosis

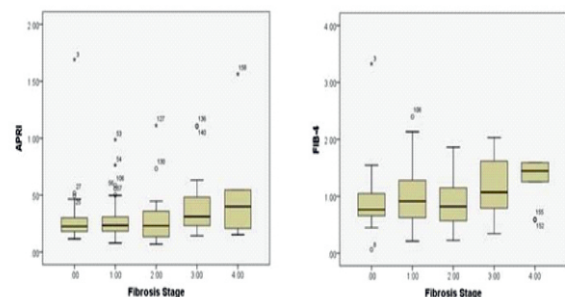


Fig.e 2: A- APRI levels according to the stage of fibrosis. B- FIB-4 levels according to the stage of fibrosis.

liver fibrosis, particularly in people with an HCV diagnosis. Given that the Wang et al. and Wu et al. cohorts had a higher prevalence of patients with severe cirrhosis and fibrosis, etc. This greater representation may have overestimated the perceived accuracy of non-invasive exams.

The slightly better results for APRI in their study could be due to differences in study populations. Despite some support for APRI, it is not the best option and has limited use for identifying severe fibrosis in CHB patients, as indicated by a supporting meta-analysis. Most research indicates that the accuracy of APRI in identifying fibrosis in individuals with congenital heart block is quite modest, even though the WHO and APASL endorse it as a useful non-invasive method. The main goals of antiviral treatment in CHB are to reduce fibrosis, suppress the virus, and prevent liver cancer and cirrhosis. Resolving liver inflammation is essential for liver regeneration, where new hepatocytes replace fibrotic tissue. Effective viral suppression is crucial in this process for chronic viral hepatitis. Several trials have shown that antiviral therapies effective against HBV significantly aid fibrosis regression. Notably, fibrosis can be completely reversible with the right antiviral treatment, especially if identified early. The level of fibrosis that warrants antiviral treatment is known as the "significant fibrosis level" and corresponds to METAVIR 2. Distinguishing this level from no or moderate fibrosis is a critical challenge. Consequently, these results might create the impression that these tests are overly effective at diagnosing problems. Many studies evaluating non-invasive testing often omit comparisons between individuals with minimal or moderate fibrosis and those with substantial fibrosis (METAVIR 2). In contrast, our study examined how well non-invasive diagnostics could differentiate between individuals with METAVIR 0/1 and those with METAVIR 2. APRI and FIB-4 did not demonstrate sufficient ability to distinguish between no or moderate fibrosis and substantial fibrosis. The relationship between antiviral therapies and non-invasive diagnostic techniques is underexplored, and their effectiveness in monitoring antiviral treatment has shown varied outcomes. In their study, Tenggara et al. reported a significant decline in APRI scores one year after starting antiviral therapy, closely matching the transient elastography (TE) measurement of a significant reduction in liver stiffness. They suggested that APRI would be a useful tool for monitoring antiviral therapy. However, Stasi et al. found notable histological improvements in liver biopsy samples obtained after antiviral therapy, with a correlation

between lower Forns scores and reduced liver stiffness on TE. In our research, APRI and FIB-4 scores did not significantly decline after antiviral treatment. Since our patients did not undergo post-treatment liver biopsies, further conclusions were limited by the data available.


CONCLUSION

Future studies should focus on refining these methods and validating their utility across diverse populations. The accuracy of diagnosis and patient outcomes can be further enhanced by combining many non-invasive techniques. The results of this investigation indicate that non-intrusive diagnostic approaches such as APRI and FIB-4 are not effective in distinguishing between significant and severe/advanced fibrosis versus moderate or absent fibrosis in individuals who suffer from HBeAg-negative chronic hepatitis B. People who are mild fibrosis who do not require antiviral treatment may face unnecessary healthcare expenditures and potential side effects from medications if these tests are not modified.

REFERENCES

1. Lampertico P. EASL 2017 Clinical Practice Guidelines on the management of hepatitis B virus infection. *J Hepatol.* 2017;67:29.
2. Schweitzer A, Horn J, Mikolajczyk RT, Krause G, Ott JJ. Estimations of worldwide prevalence of chronic hepatitis B virus infection: a systematic review of data published between 1965 and 2013. *The Lancet.* 2015;386:1546–55.
3. Funk ML, Rosenberg DM, Lok ASF. World-wide epidemiology of HBeAg-negative chronic hepatitis B and associated precore and core promoter variants. *J Viral Hepat.* 2002;9:52–61.
4. Saikia N, Talukdar R, Mazumder S, Khanna S, Tandon R. Management of patients with HBeAg-negative chronic hepatitis B. *Postgrad Med J.* 2007;83:32–9.
5. Azmi AN. Practical approach in hepatitis B e antigen-negative individuals to identify treatment candidates. *World J Gastroenterol.* 2014;20:12045.
6. Kumar M, Sarin SK, Hissar S, Pande C, Sakhuja P, Sharma BC, et al. Virologic and histologic features of chronic hepatitis B virus-infected asymptomatic patients with persistently normal ALT. *Gastroenterology.* 2008;134:9.
7. Terrault NA, Lok ASF, McMahon BJ, Chang K-M, Hwang JP, Jonas MM, et al. Update on prevention, diagnosis, and treatment of chronic

- hepatitis B: AASLD 2018 hepatitis B guidance. *Hepatology*. 2018;67:1560–99.
8. Bravo AA, Sheth SG, Chopra S. Liver Biopsy. *N Engl J Med* 2001;344:495–500.
 9. Regev A, Berho M, Jeffers LJ, Milikowski C, Molina EG, Pyrsopoulos NT, et al. Sampling error and intraobserver variation in liver biopsy in patients with chronic HCV infection. *Am J Gastroenterol*. 2002;97:2614–8.
 10. Wang H-W, Peng C-Y, Lai H-C, Su W-P, Lin C-H, Chuang P-H, et al. New noninvasive index for predicting liver fibrosis in Asian patients with chronic viral hepatitis. *Sci Rep*. 2017;7:3259.
 11. Dimzova M, Kondova-Topuzovska I, Bosilkovski M, Ivanovski L, Milenkovic Z, Semenakova-Cvetkovska V, et al. Noninvasive biomarkers in assessment of liver fibrosis in patients with hbeag negative chronic hepatitis B. *Open Access Maced J Med Sci*. 2018;6:1052–8.
 12. Nallagangula KS, Nagaraj SK, Venkataswamy L, Chandrappa M. Liver fibrosis: a compilation on the biomarkers status and their significance during disease progression. *Future Sci OA*. 2018;4:FSO250.
 13. Singh S, Muir AJ, Dieterich DT, Falck-Ytter YT. American Gastroenterological Association Institute Technical Review on the role of elastography in chronic liver diseases. *Gastroenterology*. 2017;152:1544–77.
 14. Teshale E, Lu M, Rupp LB, Holmberg SD, Moorman AC, Spradling P, et al. APRI and FIB-4 are good predictors of the stage of liver fibrosis in chronic hepatitis B: the Chronic Hepatitis Cohort Study (CHeCS). *J Viral Hepat*. 2014;21:917–20.
 15. Trembling PM, Lampertico P, Parkes J, Tanwar S, Viganò M, Facchetti F, et al. Performance of enhanced liver fibrosis test and comparison with transient elastography in the identification of liver fibrosis in patients with chronic hepatitis B infection. *J Viral Hepat*. 2014;21(6):430–8.
 16. Wong GL-H. Non-invasive assessments for liver fibrosis: The crystal ball we long for: Assessments for liver fibrosis. *J Gastroenterol Hepatol*. 2018;33:1009–15.
 17. Stasi C, Salomoni E, Arena U, Corti G, Montalto P, Bartalesi F, et al. Non-invasive assessment of liver fibrosis in patients with HBV-related chronic liver disease undergoing antiviral treatment: A preliminary study. *Eur J Pharmacol*. 2017;806:105–109.
 18. Tenggara IR, Lesmana CRA, Gani RA. Treatment response monitoring of chronic hepatitis B patients using transient elastography and aspartate aminotransferase-to-platelet ratio index (APRI). *Acta Med Indones*. 2017;49:7.
 19. Yalaki S, Yalcin MS. Does regression in treatment-induced liver fibrosis reflect noninvasive tests? Assessing treatment results of hepatitis B patients who took potent antiviral drugs for 5 years. *Niger J Clin Pract*. 2020;23(2):226–231.
 20. Nguyen LH, Chao D, Lim JK, Ayoub W, Nguyen MH. Histologic changes in liver tissue from patients with chronic hepatitis B and minimal increases in levels of alanine aminotransferase: a meta-analysis and systematic review. *Clin Gastroenterol Hepatol*. 2014;12:1262–6.
 21. Charre C, Levrero M, Zoulim F, Scholtès C. Non-invasive biomarkers for chronic hepatitis B virus infection management. *Antiviral Res*. 2019;169:104553.
 22. Bedossa P, Dargere D, Paradis V. Sampling variability of liver fibrosis in chronic hepatitis C. *Hepatology*. 2003;38:1449–57.
 23. Castera L. Assessing liver fibrosis. *Expert Rev Gastroenterol Hepatol*. 2008;2:541–52.
 24. Chin JL, Pavlides M, Moolla A, Ryan JD. Non-invasive markers of liver fibrosis: adjuncts or alternatives to liver biopsy?. *Front Pharmacol*. 2016;7.
 25. Li S, Sun X, Chen M, Ying Z, Wan Y, Pi L, et al. Liver fibrosis conventional and molecular imaging diagnosis update. *J Liver*. 2019;8(1):236.
 26. Petitclerc L, Sebastiani G, Gilbert G, Cloutier G, Tang A. Liver fibrosis: Review of current imaging and MRI quantification techniques: Imaging of Liver Fibrosis. *J Magn Reson Imaging*. 2017;45:1276–95.
 27. Joo SK, Kim JH, Oh S, Kim BG, Lee KL, Kim HY, et al. Prospective comparison of noninvasive fibrosis assessment to predict advanced fibrosis or cirrhosis in Asian patients with hepatitis C. *J Clin Gastroenterol*. 2015;49:697–704.
 28. Vallet-Pichard A, Mallet V, Nalpas B, Verkarre V, Nalpas A, Dhalluin-Venier V, et al. FIB-4: An inexpensive and accurate marker of fibrosis in HCV infection. comparison with liver biopsy and fibrotest. *Hepatology*. 2007;46:32–6.
 29. Wu S-D. Staging of liver fibrosis in chronic hepatitis B patients with a composite predictive

- model: A comparative study. *World J Gastroenterol.* 2010;16:501.
30. Huang R, Wang G, Tian C, Liu Y, Jia B, Wang J, et al. Gamma-glutamyl-transpeptidase to platelet ratio is not superior to APRI, FIB-4 and RPR for diagnosing liver fibrosis in CHB patients in China. *Sci Rep.* 2017;7:8543.
 31. Kim WR, Berg T, Asselah T, Flisiak R, Fung S, Gordon SC, et al. Evaluation of APRI and FIB-4 scoring systems for non-invasive assessment of hepatic fibrosis in chronic hepatitis B patients. *J Hepatol.* 2016;64:773–80.
 32. Koksall AR, Alkim H, Boga S, Ergun M, Bayram M, Ozguven BY, et al. Effect of entecavir and tenofovir treatment on noninvasive fibrosis scores: which one is better? *Am J Ther.* 2016;23:e429–38.
 33. Jin W, Lin Z, Xin Y, Jiang X, Dong Q, Xuan S. Diagnostic accuracy of the aspartate aminotransferase-to-platelet ratio index for the prediction of hepatitis B-related fibrosis: a leading meta-analysis. *BMC Gastroenterol.* 2012;12:14.
 34. Zeng D-W, Dong J, Liu Y-R, Jiang J-J, Zhu Y-Y. Noninvasive models for assessment of liver fibrosis in patients with chronic hepatitis B virus infection. *World J Gastroenterol.* 2016;22:6663.
 35. Calvaruso V, Craxi A. Regression of fibrosis after HBV antiviral therapy. Is cirrhosis reversible? *Liver Int.* 2014;34:85–90.
 36. Bedossa P. Reversibility of hepatitis B virus cirrhosis after therapy: who and why? *Liver Int.* 2015;35:78–81.
 37. Li X, Jin Q, Xu H, Zhang Z, Zhou H, Yan D, et al. Chronic hepatitis B patients with high liver fibrosis levels should receive antiviral treatment. *Exp Ther Med.* 2017;13:3624–30.
 38. Marcellin P, Gane E, Buti M, Afdhal N, Sievert W, Jacobson IM, et al. Regression of cirrhosis during treatment with tenofovir disoproxil fumarate for chronic hepatitis B: a 5-year open-label follow-up study. *The Lancet.* 2013;381:468–75.
 39. Schiff ER, Lee SS, Chao Y, Kew Yoon S, Bessone F, Wu S, et al. Long-term treatment with entecavir induces reversal of advanced fibrosis or cirrhosis in patients with chronic hepatitis B. *Clin Gastroenterol Hepatol.* 2011;9:274-276.e1.
 40. EASL-ALEH Clinical Practice Guidelines: Non-invasive tests for evaluation of liver disease severity and prognosis. *J Hepatol.* 2015;63:237–64.
- 

Orcid ID:

Meral Sozen - <https://orcid.org/0000-0001-5915-0319>

How to cite this article:

Sozen m. Assessment Of Non-invasive Tests In HBEAG-negative Chronic Hepatitis B. *Era J. Med. Res.* 2024; 11(1): 153-159.

Licencing Information

Attribution-ShareAlike 2.0 Generic (CC BY-SA 2.0) Derived from the licencing format of creative commons & creative commons may be contacted at <https://creativecommons.org/> for further details.